

# Laser Angioplasty of Restenosed Coronary Stents: Results of a Multicenter Surveillance Trial

Ralf Köster, MD,<sup>1</sup> Christian W. Hamm, MD, FACC,<sup>1</sup> Ricardo Seabra-Gomes, MD, FACC,<sup>2</sup> Gunhild Herrmann, MD,<sup>3</sup> Horst Sievert, MD,<sup>4</sup> Carlos Macaya, MD,<sup>5</sup> Eckart Fleck, MD,<sup>6</sup> Klaus Fischer, MD,<sup>7</sup> Johannes J.R.M. Bonnier, MD, PhD,<sup>8</sup> Jean Fajadet, MD,<sup>9</sup> Jürgen Waigand, MD,<sup>10</sup> Karl-Heinz Kuck, MD, FACC,<sup>11</sup> Michel Henry, MD,<sup>12</sup> Marie Claude Morice, MD,<sup>13</sup> Luciano Pizzulli, MD,<sup>14</sup> Michael M. Webb-Peploe, MD,<sup>15</sup> Arnd B. Buchwald, MD,<sup>16</sup> Lars Ekström, MD,<sup>17</sup> Eberhard Grube, MD,<sup>18</sup> Saad Al Kasab, MD, FACC,<sup>19</sup> Antonio Colombo, MD, FACC,<sup>20</sup> Archimedes Sanati, MD,<sup>21</sup> Sjeff M.P.G. Ernst, MD,<sup>22</sup> Michael Haude, MD,<sup>23</sup> Martin B. Leon, MD, FACC,<sup>24</sup> Charles Ilsley, MD,<sup>25</sup> Rafael Beyar, MD, FACC,<sup>26</sup> Yvo Taeymans, MD,<sup>27</sup> Uwe Gladbach,<sup>28</sup> Karl Wegscheider, PhD,<sup>29</sup> Patrick W. Serruys, MD, PhD, FACC,<sup>30</sup> for the Laser Angioplasty of Restenosed Stents (LARS) Investigators

*Hamburg, Germany; Lisbon, Portugal; Kiel, Germany; Frankfurt, Germany; Madrid, Spain; Berlin, Germany; Hannover, Germany; Eindhoven, The Netherlands; Toulouse, France; Nancy, France; Antony, France; Bonn, Germany; London, England; Göttingen, Germany; Gotenburg, Sweden; Siegburg, Germany; Riyadh, Saudi Arabia; Milan, Italy; Tehran, Iran; Nieuwegein, The Netherlands; Essen, Germany; Washington, D.C.; Harefield, England; Haifa, Israel; Ghent, Belgium, and Rotterdam, The Netherlands*

- 
- OBJECTIVES** This study evaluated safety and efficacy of excimer laser angioplasty for treatment of restenosed or occluded coronary stents.
- BACKGROUND** Balloon angioplasty of in-stent restenosis is limited by a high recurrence rate. Debulking by laser angioplasty is a novel concept to treat in-stent restenosis.
- METHODS** A total of 440 patients with restenoses or occlusions in 527 stents were enrolled for treatment with concentric or eccentric laser catheters and adjunctive balloon angioplasty.
- RESULTS** Laser angioplasty success ( $\leq 50\%$  diameter stenosis after laser treatment or successful passage with a 2.0-mm or 1.7-mm eccentric laser catheter) was achieved in 92% of patients. Adjunctive balloon angioplasty was performed in 99%. Procedural success (laser angioplasty success followed by  $\leq 30\%$  stenosis with or without balloon angioplasty) was 91%. There was neither a significant difference in success with respect to lesion length, nor were there differences between small and large vessels or native vessels and vein grafts. Success was higher and residual stenosis lower using large or eccentric catheters. Serious adverse events included death (1.6%, not directly laser catheter related), Q-wave myocardial infarction (0.5%), non-Q-wave infarction (2.7%), cardiac tamponade (0.5%) and stent damage (0.5%). Perforations after laser treatment occurred in 0.9% of patients and after balloon angioplasty in 0.2%. Dissections were visible in 4.8% of patients after laser treatment and in 9.3% after balloon angioplasty. Reinterventions during hospitalization were necessary in 0.9% of patients; bypass surgery was performed in 0.2%.
- CONCLUSIONS** Excimer laser angioplasty with adjunctive balloon angioplasty is a safe and efficient technology to treat in-stent restenoses. These data justify a randomized comparison with balloon angioplasty. (J Am Coll Cardiol 1999;34:25–32) © 1999 by the American College of Cardiology
- 

From the <sup>1</sup>Medical Clinic, Department of Cardiology, University Hospital Eppendorf, Hamburg, Germany; <sup>2</sup>Hospital Santa Cruz, Lisbon, Portugal; <sup>3</sup>Department of Medicine, Christian-Albrechts University, Kiel, Germany; <sup>4</sup>Cardiovascular Center Bethanien, Frankfurt, Germany; <sup>5</sup>University Hospital San Carlos, Madrid, Spain; <sup>6</sup>German Heart Institute, Berlin, Germany; <sup>7</sup>Clementinen Hospital, Hannover, Germany; <sup>8</sup>Catharina Hospital, Eindhoven, The Netherlands; <sup>9</sup>Clinique Pasteur, Toulouse, France; <sup>10</sup>Humboldt-University Berlin, Franz Volhard Clinic, Berlin, Germany; <sup>11</sup>St. George Hospital, Hamburg, Germany; <sup>12</sup>Clinique de Essey, Nancy, France; <sup>13</sup>Clinique du Bois de Verrieres, Antony, France; <sup>14</sup>University Hospital, University of Bonn, Bonn, Germany; <sup>15</sup>St. Thomas' Hospital, London University, London, England; <sup>16</sup>University Clinic, Göttingen, Germany; <sup>17</sup>Sahlgrenska University Hospital, Gotenburg, Sweden; <sup>18</sup>Siegburg Hospital, Siegburg, Germany; <sup>19</sup>Prince

Sultan Cardiac Center, Riyadh, Saudi Arabia; <sup>20</sup>Centro Cuore Columbus, Milan, Italy; <sup>21</sup>Sharyati Hospital, Tehran, Iran; <sup>22</sup>Antonius Hospital, Nieuwegein, The Netherlands; <sup>23</sup>University Hospital, Essen, Germany; <sup>24</sup>Washington Hospital Center, Washington, D.C.; <sup>25</sup>Harefield Hospital, Harefield, England; <sup>26</sup>Rambam Medical Center, Haifa, Israel; <sup>27</sup>University Hospital Ghent, Ghent, Belgium; <sup>28</sup>Spectranetics, Inc., Nieuwegein, The Netherlands; <sup>29</sup>Wegscheider Biometry and Statistics, Inc., Berlin, Germany, and <sup>30</sup>University Hospital Dijkzigt, Thoraxcenter, Erasmus University, Rotterdam, The Netherlands. This study was supported by Spectranetics Inc., B.V., Nieuwegein, The Netherlands.  
Manuscript received March 3, 1998; revised manuscript received February 23, 1999, accepted March 24, 1999.

**Abbreviations and Acronyms**

ACT	= activated clotting time
CK	= creatine kinase
PTCA	= percutaneous transluminal coronary angioplasty

In-stent restenosis is an increasingly important clinical problem. Percutaneous transluminal coronary angioplasty (PTCA) is currently the most widely used treatment modality for this type of lesion (1). However, the recurrence rate for dilated restenotic stents is considerably higher than for nonstented restenotic lesions and has been reported to be as high as 85% (2–6). Therefore, the treatment of in-stent restenosis remains a therapeutic challenge.

Previous studies identified a large acute luminal gain after coronary interventions as a predictor of a low restenosis rate, which gave rise to the “bigger is better” hypothesis (7–10). This theory has been further supported by data from laser angioplasty for debulking of nonstented coronary lesions (11,12). Lesions within stents appear to be even more suitable for ablation than nonstented lesions, because the initial lumen gain in stented lesions is most commonly large and restenotic stents may contain a considerable amount of tissue. This restenotic tissue within stents is soft, usually does not contain calcifications and should therefore be easy to ablate by laser (13). Ablation of plaque mass appears to be a promising approach, since conventional PTCA does not remove tissue (14). We hypothesized that primary debulking of in-stent restenosis by means of laser angioplasty achieves a better result with a greater luminal gain compared with treatment with PTCA alone. Therefore we conducted this prospective multicenter surveillance trial to evaluate the feasibility, safety and efficacy of excimer laser angioplasty with saline flush and adjunctive PTCA for the treatment of in-stent restenosis.

**METHODS**

**Patients.** Between May 1996 and July 1997 excimer laser angioplasty of in-stent restenosis was performed in 440 consecutive patients at 28 clinical centers. Patients were included in the study if they had a restenosis >70% or a wireable total occlusion within a stent, implanted for >1 month in a native vessel or a bypass graft with a diameter  $\geq 2.5$  mm on visual assessment. Patients with an evolving myocardial infarction and angiographic evidence of fresh thrombus were excluded.

The study was performed in a prospective and nonrandomized design. Written informed consent was obtained from all patients under a protocol approved by the ethics committee of the Hamburg medical board and of the participating centers. The study was carried out according to the principles of the Declaration of Helsinki.

Clinical and angiographic information were recorded on

standardized forms for entry into a computerized database. Angina pectoris was graded by the individual investigators using the classification of the Canadian Cardiovascular Society (15). Angiograms were analyzed at the participating centers by visual assessment, caliper technique or computerized quantitative coronary angiography. Follow-up included evaluation of clinical status up to hospital discharge.

**Excimer laser system.** A xenon chloride excimer laser unit (Spectranetics CVX-300™, Spectranetics, Colorado Springs, Colorado) was utilized in all patients. Laser energy was delivered through concentric or eccentric multifiber catheters (Vitesse CII™ or Vitesse E II™, Spectranetics) 1.4, 1.7 or 2.0 mm in diameter. The decision to use a concentric or an eccentric catheter and the choice of the catheter size and number was left to the investigator. The operators were advised to debulk as much tissue as possible.

**Laser angioplasty procedure and definitions.** All patients were treated with oral aspirin (100 mg/day or 300 mg/day if the patient was not on aspirin therapy before). A standard angioplasty regimen of heparin (10,000 U intravenous bolus injection) and intracoronary nitroglycerin (100 to 200  $\mu$ g) was administered before baseline coronary angiography was performed. The protocol called for further administration of heparin if this was necessary to keep the activated clotting time (ACT) >300 s during prolonged procedures. High dose heparin therapy was discontinued immediately after the coronary intervention. If there was evidence of intracoronary thrombus high dose heparin therapy was continued at the discretion of the operator and according to local clinical practice. After laser intervention the treatment with aspirin 100 mg/day was routinely continued in all patients. If there was an indication to use abciximab, such as the evidence of intracoronary thrombus, the operator was allowed to use abciximab. The abciximab and heparin therapy and monitoring was performed according to local clinical practice.

Lesions were classified as focal or diffuse according to the operator's discretion. Only one lesion was treated per patient. Intracoronary infusion of 0.9% sodium chloride solution was performed during excimer laser treatment. The laser catheter was advanced at a speed of 1 mm/s across the lesion. Multiple passes with the catheter were made through the lesion at the operator's discretion. Adjunctive PTCA had to be performed if the residual stenosis after laser treatment was  $\geq 50\%$ . If the residual stenosis after laser treatment was <50% the investigator was encouraged to use adjunctive PTCA if this could potentially optimize the result. Adjunctive PTCA was performed according to standard clinical practice. Stents were used if necessary to optimize the result if PTCA was insufficient.

**Angiographic and clinical evaluation.** Laser angioplasty success was defined as  $\leq 50\%$  residual stenosis after laser angioplasty or a successful pass with a 2.0-mm or an eccentric 1.7-mm laser catheter. In addition to common

angiographic criteria, procedural success criteria were included in this safety and efficacy study, since one clinically essential aspect of laser technique is feasibility to pass a stent with the catheter. Because larger laser catheters could potentially be caught in the stent struts, a complete passage was an important determinant for success. Procedural success was defined as laser angioplasty success followed by a  $\leq 30\%$  residual stenosis in all angiographic views postprocedure, with or without the use of adjunctive PTCA, on visual assessment. Clinical success was defined as procedural success without the occurrence of serious adverse events before hospital discharge.

Serious adverse events included death, Q-wave and non-Q-wave myocardial infarction, recurrent PTCA, coronary artery bypass surgery, cardiac tamponade and stent damage.

Death was defined as in-hospital death from any cause (procedural or other) either during or after the laser procedure. Q-wave infarction was defined as ST-segment elevation  $\geq 0.1$  mV in  $\geq 2$  electrocardiographic leads plus creatine kinase (CK) elevation  $> 2$  times above normal value associated with  $> 6\%$  CK, MB fraction and the development of new pathologic Q waves according to the Minnesota Code (16). A non-Q-wave infarction was diagnosed if there was a CK elevation with the presence of  $> 6\%$  MB fraction without the development of pathologic Q waves. Re-PTCA was defined as PTCA of the target lesion during hospital stay. Coronary artery bypass surgery was defined as bypass surgery performed for any cause during hospital stay. Cardiac tamponade was defined as a pericardial effusion with hemodynamically significant compression of cardiac ventricles. Stent damage was defined as any form of disformation or dislocation besides normal expansion, with or without clinical sequelae.

Complications after excimer laser angioplasty and after adjunctive PTCA included coronary dissection, haziness, "no reflow," incomplete passage, perforation, acute vessel closure, intracoronary thrombus and embolism.

Dissection was defined as intramural lucency or irregularity within or beyond the margin of the lesions, whether or not this resulted in arterial closure or other clinical complications. Haziness was defined as inhomogeneity of contrast filling. No reflow was a transient marked reduction of blood flow in the procedural vessel. Incomplete passage was defined as inability to pass the stent with the laser catheter. Perforation was diagnosed if there was an extravasation of contrast medium beyond the adventitia of the artery with or without associated clinical complications. Acute closure was defined as angiographic persistent reduction of blood flow in the procedural vessel with or without clinical or electrocardiographic evidence of myocardial ischemia. Intracoronary thrombus was defined as development of intraluminal lucency, filling defect or staining consistent with angiographic appearance of thrombus. Coronary embolism was defined as downstream focal obstruction not reversible with nitroglycerin administration.

**Statistical analysis.** Clinical records were analyzed at Wegscheider Biometry and Statistics, Berlin, Germany. The patient was the unit of analysis unless otherwise stated. Comparison of success rates by unordered categories were performed using ordinary chi-square tests. Comparisons of continuous variables by unordered categories were performed using Kruskal-Wallis tests. Comparisons of success rates by ordered categories were performed using the exact Mann-Whitney *U* test. Continuous variables were presented as mean  $\pm$  SD and their range. A *p* value of  $< 0.05$  was considered significant.

## RESULTS

**Patients and lesion characteristics.** A total of 440 patients were enrolled in the study. The mean age of the patients was  $61 \pm 10$  years, and 81% were male (age range 30 to 86 years). According to the Canadian Cardiovascular Society classification (15), 69 patients (16%) suffered from angina pectoris graded as class I, 144 patients (33%) were graded as class II, 164 (37%) as class III and 63 (14%) as class IV.

The patients who were intended for treatment with excimer laser angioplasty had a total of 527 stents within the vessels (139 Applied Vascular Engineering, 101 Palmaz-Schatz, 48 Gianturco-Roubin, 43 Wiktor, 31 Multilink, 24 Wallstents and 141 other stents). Two hundred eighty-seven patients had 1 stent/vessel and 151 patients had  $\geq 2$  stents/vessel. The interval since implantation was  $7.5 \pm 7.9$  months. Stents had previously been implanted with balloons  $3.3 \pm 0.4$  mm in diameter (range 2.50 to 4.50 mm) and had previously been overdilated in 47 patients (11%). They had been expanded equal to the vessel reference diameter in 355 patients (81%) and had been underdilated in 35 patients (8%) (values of three patients were missing).

Most of the 440 lesions ( $n = 388$ , 88%) involved native coronary arteries. In the left anterior descending artery there were 209 lesions (54%), in the left circumflex artery there were 57 lesions (15%) and in the right coronary artery there were 122 (31%) lesions. Twelve percent of the lesions ( $n = 52$ ) were located in saphenous vein grafts. Stents were located in a straight vessel segment in 84% of patients, at a major side branch in 8%, within a curved segment  $> 60^\circ$  in 3%, proximal to a curve of  $> 60^\circ$  in 2% and distal to a curve of  $60^\circ$  in 3% of the patients. The length of the stented vessel segment was  $24 \pm 15$  mm (range 6 to 105 mm, 93% were  $> 10$  mm in length). Of the 440 lesions, 365 were stenoses  $\geq 70\%$  (83%), 37 were subtotal occlusions (8%) and 38 were totally occluded (9%). Coronary flow was graded according to the Thrombolysis in Myocardial Infarction classification (17) as grade 3 in 285 patients (65%), grade 2 in 83 patients (19%), grade 1 in 34 patients (7%) and grade 0 in 38 patients (9%). The morphology of the in-stent restenosis was focal in 85 patients (19%) and diffuse in 321 patients (71%). The lesion was located at the stent ends in 46 patients (10%). The length of the restenosis was  $19 \pm 14$  mm (range 2 to 105 mm, 82% were  $> 10$  mm in length).



The vessel diameter on visual assessment was  $3.17 \pm 0.45$  mm (range 1.40 to 5.20 mm) proximal to the stent and  $2.96 \pm 0.51$  mm (range 1.80 to 5.20 mm) distal to the stent.

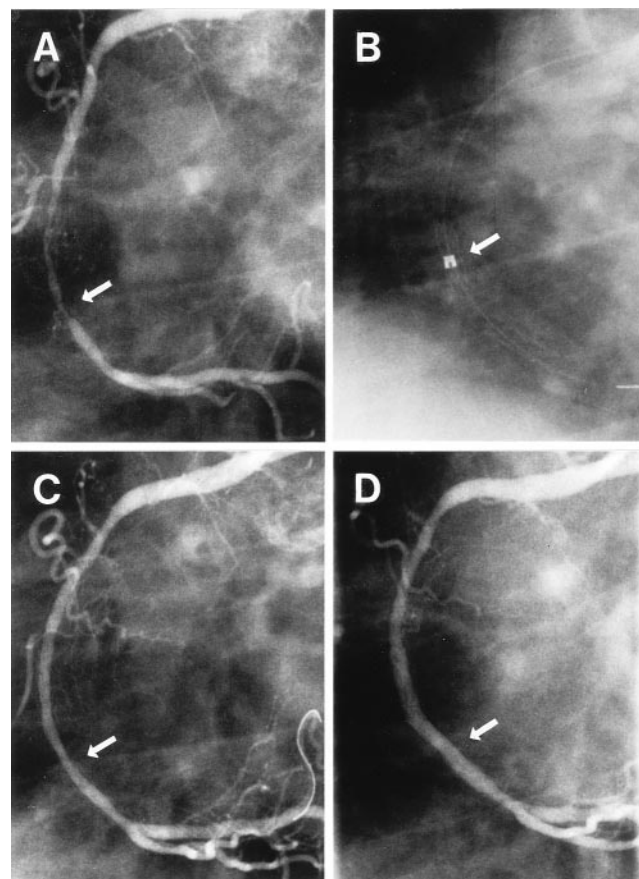
**Laser catheters and energies used.** The choice of the guiding catheter size was dependent on the diameter of the laser catheter used. The size of the guiding catheter was 6 F in 4 patients (1%), 7 F in 44 patients (10%), 8 F in 372 patients (85%) and 9 F in 20 patients (4%). The 477 laser catheter types used were 1.4 mm concentric in 38 patients (8%), 1.7 mm concentric in 88 patients (18%), 1.7 mm eccentric in 221 patients (46%), 2.0 mm concentric in 102 patients (22%) and 2.0 mm eccentric in 28 patients (6%). Laser catheters were activated with a maximum fluency of  $49 \pm 5$  mJ/mm<sup>2</sup> and a repetition rate of  $26 \pm 4$  Hz. During  $4.6 \pm 4.0$  passes through the lesion  $1,458 \pm 1,028$  pulses were delivered. In 404 patients (92%) one catheter was necessary and in 36 patients (8%) two or more catheters of different sizes were used to optimize the result. In 436 patients (99%) saline flush was performed. In four patients, in whom 7-F guiding catheters were used, saline flush was not feasible.

**Angiographic analysis.** Excimer laser angioplasty of in-stent restenosis was attempted in 440 patients. In 433 patients (98%) the laser catheters were able to cross the in-stent restenosis and laser angioplasty was feasible (Fig. 1).

Diameter stenosis was  $>70\%$  in all 440 patients before intervention and was significantly reduced to  $41 \pm 17\%$  by laser treatment ( $p < 0.0001$ ). In 64% of the patients, the diameter stenosis was reduced to  $<50\%$ . By the use of large or eccentric laser catheters the residual stenosis after laser treatment was significantly lower as compared with concentric and smaller catheters (Table 1). Consequently, treatment with the eccentric 2.0-mm catheter achieved the lowest residual stenoses ( $33 \pm 12\%$ ), without an increase of complications (Table 1).

In 10 patients with vessel diameters of approximately 2.50 mm on visual assessment the resulting catheter/vessel ratios were  $>0.8$ . Residual stenosis was significantly lower ( $30 \pm 14\%$ ) if the catheter/vessel ratios were  $>0.8$  versus  $\leq 0.8$  ( $41 \pm 17\%$ ) ( $p = 0.04$ ). The incidence of myocardial infarctions and dissections was independent from the catheter size and the catheter size/vessel size ratio. However, there was a nonsignificant trend toward a higher occurrence of dissections if larger or eccentric catheters were used (Table 1).

Adjunctive PTCA was performed in 437 of 440 patients (99%) with balloons inflated up to  $13 \pm 4$  atm (range 4 to 25 atm). The balloons had a nominal diameter of  $3.35 \pm 0.43$  mm (range 2.00 to 6.00 mm) and a length of  $25 \pm 10$  mm. The stenosis was reduced to a final diameter of  $7 \pm 13\%$  (range  $-20\%$  to  $100\%$ ) ( $p < 0.0001$ ). After PTCA, stents were expanded equal to the reference diameter in 339 patients (78%). In 66 patients (15%) stents were overdilated, and in 32 patients (7%) stents remained underdilated.



**Figure 1.** (A) Coronary angiogram with an in-stent restenosis (arrow) of a right coronary artery with three implanted Palmaz-Schatz stents. (B) Eccentric laser catheter with 2.0-mm tip (arrow) advanced in the stented portion of the vessel. The radiopaque marker band at the catheter tip, which allows control over the catheter rotation, is clearly visible. (C) Smooth ablation of plaque after multiple passes with the laser catheter under continuous saline flush (arrow). (D) Final angiogram after adjunctive percutaneous transluminal coronary angioplasty of the lesion (arrow).

Laser angioplasty success was 92%. Procedural success, defined as laser angioplasty success followed by a  $\leq 30\%$  residual stenosis with or without PTCA, was 91%. A final result with a residual stenosis of  $<30\%$  was achieved in 96% of the patients. This result includes the patients with additional stent implantations. After excimer laser angioplasty and adjunctive PTCA Thrombolysis in Myocardial Infarction 3 flow was achieved in 99% of the patients.

**Complications and serious adverse events.** Complications after laser treatment and after adjunctive PTCA are presented in Table 2. Dissections typically appeared outside of the stents. Vessel perforations with subsequent cardiac tamponade occurred in two patients (0.5%). One of these patients was treated medically, the other with percutaneous drainage. Stent damage remained without significant clinical sequelae in both patients with this event. Other complications after laser treatment included coronary vasospasm in three patients, and distal embolization, thrombus and

**Table 1.** Patients With Complications and Residual Diameter Stenoses by Largest Diameter Catheter Used

Catheter Type	Myocardial Infarction	Dissections	Perforations	Residual Stenosis (%)
1.4 C	0 (0%)	1 (4.5%)	0 (0%)	43
1.7 C	2 (0.5%)	2 (2.5%)	0 (0%)	47
1.7 E	6 (1.4%)	8 (3.8%)	1 (0.5%)	41
2.0 C	3 (0.7%)	7 (6.9%)	2 (2%)	39
2.0 E	1 (0.2%)	3 (11%)	0 (0%)	33
	p = NS	p = NS	p = NS	p = 0.002

C = concentric; E = eccentric.

ventricular fibrillation in one patient each. In two patients a temporary third-degree atrioventricular block occurred, which had no clinical sequelae. In one patient a lesion proximal to the stent could not be crossed.

Other complications after PTCA included side branch occlusions in five patients, and vessel closure due to embolism, distal slow flow and a thrombotic occlusion of an aortocoronary bypass graft in one patient each.

In 75 patients (17%) 86 additional stents were implanted to optimize the result: stents were implanted to treat dissections (33 patients), haziness (13 patients), no reflow (1 patient), acute or threatened closure (2 patients), perforations (2 patients) and other reasons (24 patients) such as the treatment of nontarget lesions or for bridging of gap stenoses.

The hospital stay was  $3.6 \pm 2.8$  days (range 1 to 23 days, 61% of the patients stayed  $\leq 4$  days in hospital). In-hospital follow-up revealed serious adverse events in 37 patients (8%), including stent dislodgment. In-hospital death occurred in seven patients (1.6%); however, none of these deaths were directly caused by the treatment with the laser catheter itself. One of these patients died from cardiogenic shock due to the occlusion of a nontarget vessel during a diagnostic coronary angiography. One patient underwent an angioplasty of the carotid artery 20 days after the laser intervention and died from intracerebral bleeding after the intervention at the carotid artery performed during the same hospital stay. Two patients who received abciximab died

from cerebral bleedings probably related to the abciximab therapy. In one of these patients abciximab had been combined with high dose heparin. Three other patients treated with high dose heparin during the procedure (up to 25,000 IE) who also received ticlopidine and acetylsalicylic acid died due to cerebral bleeding.

There were two Q-wave infarctions (0.5%) with a maximum CK value of 1024 U/liter. Non-Q-wave infarctions occurred in 12 patients (2.7%). Recurrent PTCA during hospitalization was performed in four patients (0.9%). Bypass surgery during the hospitalization for laser angioplasty was necessary in one patient (0.2%). Stent damage and cardiac tamponade occurred in two patients (0.5%) each. One of the damaged stents was a Wiktor coil stent, which had been dislodged by a guide wire. Other adverse events included one retroperitoneal hematoma, one major groin hematoma with pseudoaneurysm and three minor cerebral bleeds.

**Success rates.** Laser angioplasty success, procedural success and clinical success did not differ significantly between the first 220 patients and the second 220 patients enrolled into the study ( $p > 0.20$ ). Therefore, no significant learning effect could be observed.

Laser angioplasty success, procedural success and clinical success were similar in different vessels (left anterior descending, left circumflex and right coronary arteries) and did not differ between native vessels and saphenous vein grafts (Table 3). There was no significant difference in all success rates in the treatment of lesions of different lengths ranging from 5 to 105 mm (Table 3). There also was no significant difference between the success rates in patients with vessels of small ( $< 3.00$  mm) or larger diameter ( $\geq 3.00$  mm) (Table 4). However, laser angioplasty success, procedural success and clinical success were all significantly higher, if larger laser catheters or eccentric laser catheters were used (1.7 mm eccentric or 2.0 mm concentric or eccentric) ( $p < 0.006$ ) (Table 4).

Clinical success, defined as laser angioplasty success and procedural success in the absence of any serious adverse events, was achieved in 84% of the patients. Clinical success in the absence of myocardial infarction was achieved in 87%.

**Table 2.** Clinical Complications After Laser Treatment and Adjunctive Balloon Angioplasty in 440 Patients

Type of Complication	Intervention	
	Laser Treatment	Adjunctive PTCA
Dissection	4.8 (%)	9.3 (%)
Haziness	2.7 (%)	1.1 (%)
No reflow	2.0 (%)	0 (%)
Incomplete passage	1.6 (%)	0 (%)
Perforation	0.9 (%)	0.2 (%)
Acute closure	0.2 (%)	0.2 (%)
Other	1.8 (%)	2.5 (%)

PTCA = percutaneous transluminal coronary angioplasty.

**Table 3.** Success by Lesion Location and Lesion Length

	Patients	Laser Angioplasty Success	Procedural Success	Clinical Success
Lesion location (native)				
LAD	209 (54%)	196 (94%)	195 (93%)	180 (86%)
LCX	57 (15%)	54 (95%)	53 (93%)	50 (88%)
RCA	122 (31%)	107 (88%)	105 (86%)	100 (82%)
		p = NS	p = NS	p = NS
Lesion location				
Native vessels	388 (88%)	357 (92%)	353 (91%)	330 (85%)
Vein graft	52 (12%)	48 (92%)	45 (87%)	38 (73%)
		p = NS	p = NS	p = NS
Lesion length (mm)				
<10	77 (18%)	72 (94%)	68 (88%)	66 (86%)
10-19	179 (41%)	167 (93%)	166 (93%)	151 (84%)
20-29	97 (22%)	91 (94%)	90 (93%)	83 (86%)
≥30	85 (19%)	74 (87%)	73 (86%)	67 (79%)
		p = NS	p = NS	p = NS

LAD = left anterior descending artery; LCX = left circumflex artery; RCA = right coronary artery.

## DISCUSSION

Standard PTCA of in-stent restenosis has been shown to be limited by a high recurrent restenosis rate (4-6). Therefore there is a growing demand for alternative techniques for treatment of this new disease. This multicenter study demonstrates safety and efficacy of laser angioplasty for the treatment of in-stent restenosis.

**Angiographic and clinical success.** In the present study laser angioplasty was shown to be feasible in 99% of the patients treated. The success rate in this study was high compared with the success rate of 80% in a recently published trial with laser angioplasty without saline flush in native vessels (18). There was no significant difference in

clinical success rates in patients with long diffuse versus short lesions, in patients with lesions in native vessels versus vein grafts or with lesions in small versus large vessels. However, the use of large or eccentric laser catheters significantly reduced the residual stenosis and improved the clinical success without a higher incidence of complications if the catheter/vessel ratio remained <0.8. Thus, these data encourage use of large eccentric catheters to achieve the best angiographic and clinical results.

**Complications.** The incidence of myocardial infarctions (3.2%) was lower than in a previous large registry for the use of excimer laser angioplasty with an infarction rate of 4.4% (19) and in the more recent AMRO trial with an infarction

**Table 4.** Success by Vessel Diameter, Largest Catheter Size and Catheter/Vessel Ratio

	Patients	Laser Angioplasty Success	Procedural Success	Clinical Success
Vessel diameter (mm)				
<3.00	161 (37%)	148 (92%)	146 (91%)	131 (81%)
≥3.00	277 (63%)	255 (92%)	250 (90%)	235 (85%)
		p = NS	p = NS	p = NS
Catheter type				
1.4 C	22 (5%)	18 (82%)	18 (82%)	18 (82%)
1.7 C	79 (18%)	57 (72%)	56 (71%)	52 (66%)
1.7 E	209 (48%)	204 (98%)	200 (96%)	185 (89%)
2.0 C	102 (23%)	98 (96%)	97 (95%)	88 (86%)
2.0 E	28 (6%)	28 (100%)	27 (96%)	25 (89%)
		p < 0.001	p < 0.001	p = 0.006
Ratio catheter/vessel				
≤0.8	428 (97%)	393 (92%)	386 (90%)	357 (83%)
>0.8	10 (2%)	10 (100%)	10 (100%)	9 (90%)
		p = NS	p = NS	p = NS

C = concentric; E = eccentric.



rate of 5% (18). However, in the present study, the protocol required no standardized collection of cardiac enzymes (18). Therefore, the proportion of non-Q-wave infarctions may be underestimated. Other previous trials including atherectomy and stenting revealed markedly increased creatine kinase levels in more than 10% of the treated patients (20). Considering that only 0.5% of the patients in the present study had Q-wave infarctions, excimer laser angioplasty of in-stent restenosis appears to be a safe procedure in regard to the risk of myocardial infarction.

The rate of dissections was 14%, of which only 5% were visible after excimer laser angioplasty. Most dissections were located outside of the stents and were related to adjunctive PTCA. The laser-related dissection rate in this study was low compared with previous laser studies (18,19,21). This could be explained by the mandatory use of the saline flush protocol, which greatly reduces the number of severe dissections (22-24). In addition, the low dissection rate in this study may be explained by the scaffolding effect of the stent. These protective properties may also be responsible for the low rate of vasospasms and perforations in the present study. The perforation rate of 1% was markedly lower than that of 3% in a previous trial using excimer laser angioplasty in nonstented vessels (25).

There was an unusually high death rate in this study cohort. However, none of the deaths was directly related to the use of the laser catheter itself. The qualitative angiographic results of this study with respect to thrombus formation did not require an exceptionally frequent use of abciximab or prolonged high dose heparin therapy after laser angioplasty. Therefore the incidence of bleeding complications is not explained by a high frequency of prolonged anticoagulation with the corresponding high risk of complications. The exceptionally high incidence of cerebral bleeding in this study may be explained qualitatively by an aggressive anticoagulation treatment with high doses of abciximab or heparin. Many operators using ACT measurements to guide heparin therapy often find 10,000 U too much in some patients, resulting in increased bleeding complications. The high incidence of cerebral bleeding in this study indicates that the anticoagulatory treatment must be modified. It may be useful to titrate heparin at the start of the intervention by ACT controls. The anticoagulatory drug therapy during and, if necessary, after the intervention should be adjusted within the low therapeutic range. Minimal or no postprocedure heparin is desirable to minimize risk of bleeding, particularly if abciximab is used. With these modifications a reduction of the bleeding rate to the normal range has been demonstrated (26).

**Conclusions and clinical implications.** The benefit of laser angioplasty is apparently dependent on a critical selection of indications and technique. Two previous studies comparing laser angioplasty and PTCA suggested no beneficial effects of routine use of laser angioplasty in nonstented vessels (18,27). However, in-stent restenosis, a

different type of lesion, can be safely treated with the further developed laser technique, which has been demonstrated in this study. The results of this multicenter trial confirm the recently published encouraging single-center data regarding the safety and efficacy of the laser technique (28,29). The efficacy of in-stent laser angioplasty remains to be compared with that of other techniques like PTCA and directional or rotational atherectomy.

The present data of excimer laser angioplasty for treatment of in-stent restenosis are favorable. However, the long-term results must be awaited. A first single-center report from a matched comparison of lesions treated with excimer laser angioplasty plus PTCA versus PTCA alone showed a trend toward less frequent need for target vessel revascularization in the laser angioplasty plus PTCA group (28).

Because of the potential importance of this technology for the treatment of in-stent restenosis, it appears justified to compare it with PTCA in a randomized trial and to determine the rate of recurrent restenosis after either technique.

**Study limitation.** This study was designed as a registry without a control group. Therefore, the data must be confirmed in a controlled randomized trial.

Success was defined predominantly by the angiographic outcomes. However, the angiographic outcomes were at least partially based upon qualitative lesion grading by the investigator. This could overestimate the benefit of the technique. On the other hand, the clinical success might have been underestimated, because laser angioplasty success was a prerequisite for clinical success by the given definition. There were 8% of the patients who did not fulfill the criteria for laser angioplasty success. Using the strict definition for clinical success, these patients could not achieve clinical success at all, not even with a perfect adjunctive PTCA result without adverse event.

On-line quantitative coronary angiography was not available at all centers and no angiographic core facility was used for this registry. This may affect angiographic result liability. However, this surveillance study was focused on clinical safety rather than on angiographic details. Angiographic lumen gain and late loss measured by on-line quantitative coronary angiography and intravascular ultrasound are important issues that were beyond the scope of this surveillance study. They will be primary end points of a planned trial to compare the long-term outcome of laser angioplasty plus PTCA versus PTCA alone. However, the acute results from on-line quantitative coronary angiography were consistent with this report.

The rate of non-Q-wave infarctions (2.7%) may have been underestimated, because the protocol did not require a routine and prospective collection of cardiac enzymes in asymptomatic patients. However, the routine collection of cardiac enzymes belonged to the clinical standard in most of the centers that participated.

The length of the hospital stay for the laser intervention might be overestimated, because further hospitalization of some patients for noncardiac diagnostics or treatment was included and was not separately analyzed.

## APPENDIX

### *Laser Angioplasty of Restenosed Stents (LARS) Surveillance Trial—Steering Committee and Statistics*

**Steering Committee:** C.W. Hamm (Chairman), P.W. Serruys (Cochairman), J. Fajadet, J.J. Bonnier, R. Seabra-Gomes.

**Statistics:** K. Wegscheider.

### Acknowledgments

We thank K. Balzer and K. Lepinat from Wegscheider Biometry and Statistics for their support in the statistic analyses for this study.

**Reprint requests and correspondence:** C.W. Hamm, MD, Kerckhoff Heart Center, Dept. of Cardiology, Benekestr. 2-8, 61231 Bad Nauheim, Germany. E-mail: christian.hamm@kerckhoff.med.uni-giessen.de.

## REFERENCES

- Macander PJ, Roubin GS, Agarwal SK, Cannon AD, Dean LS, Baxely WA. Balloon angioplasty for treatment of in-stent restenosis: feasibility, safety, and efficacy. *Cathet Cardiovasc Diagn* 1994;32:125-31.
- Reimers B, Moussa I, Akiyama T, et al. Long-term clinical follow-up after successful repeat percutaneous intervention for stent restenosis. *J Am Coll Cardiol* 1997;30:186-92.
- Eltchaninoff H, Cribier A, Koning R, Tron C, Letac B. Balloon angioplasty for in-stent restenosis: immediate and 6-months clinical and angiographic results. *Eur Heart J* 1997;18 Suppl:498.
- Mintz GS, Hoffmann R, Mehran R, et al. In-stent restenosis: the Washington Hospital Center experience. *Am J Cardiol* 1998;81:7E-13E.
- Bauters C, Banos JL, Van Belle E, et al. Six-month angiographic outcome after successful repeat percutaneous intervention for in-stent restenosis. *Circulation* 1998;97:318-21.
- Russo RJ, Massullo V, Jani SK, et al. Restenting versus PTCA for in-stent restenosis with or without intracoronary radiation therapy: an analysis of the Scripps trial. *Circulation* 1997;96:I-219.
- Kuntz RE, Gibson CM, Nobuyoshi M, Baim DS. Generalized model of restenosis after conventional balloon angioplasty, stenting and directional atherectomy. *J Am Coll Cardiol* 1993;21:15-25.
- Kuntz RE, Safian RD, Carroza JP, Fishman RF, Mansour F, Baim DS. The importance of acute luminal diameter in determining restenosis after coronary atherectomy or stenting. *Circulation* 1992;86:1827-35.
- Kuntz RE, Baim DS. Defining coronary restenosis, newer clinical and angiographic paradigms. *Circulation* 1993;88:1310-23.
- Moussa I, Corvasa N, Tobis J, Moses JW, Collins M. Does incremental lumen gain with intravascular ultrasound-guided stenting have an impact on the probability of angiographic restenosis? *Circulation* 1997;96:I-409.
- Bittl JA, Kuntz RE, Estella P, Sanborn TA, Baim DS. Analysis of late lumen narrowing after excimer laser-facilitated coronary angioplasty. *J Am Coll Cardiol* 1994;23:1314-20.
- Ghazzal ZM, Burton E, Weintraub WS, et al. Predictors of restenosis after excimer laser coronary angioplasty. *Am J Cardiol* 1995;75:1012-4.
- Kearney M, Pieczek A, Haley L, et al. Histopathology of in-stent restenosis in patients with peripheral artery disease. *Circulation* 1997;95:1998-2002.
- Mehran R, Mintz GS, Popma JJ, et al. Mechanism and results of balloon angioplasty of in-stent restenosis. *Am J Cardiol* 1996;76:618-22.
- Campeau L. Grading of angina pectoris. *Circulation* 1975;54:522-33.
- Blackburn H, Keys A, Simonson E, Rautaharju P, Punsar S. The electrocardiogram in population studies: a classification system. *Circulation* 1960;21:1160-75.
- The TIMI study group. The thrombolysis in myocardial infarction (TIMI) trial. *N Engl J Med* 1985;312:932-6.
- Appelmann YE, Piek JJ, Strikwerda S, et al. Randomised trial of excimer laser coronary angioplasty versus balloon angioplasty for treatment of obstructive coronary artery disease. *Lancet* 1996;347:79-84.
- Litvack F, Eigler N, Margolis J, et al. Percutaneous excimer laser coronary angioplasty: results in the first consecutive 3000 patients. *J Am Coll Cardiol* 1994;23:323-9.
- Kugelmass AD, Cohen J, Moscucci M, Piana R, Senerchia C, Kuntz RE. Elevation of the creatine kinase myocardial isoform following otherwise successful directional coronary atherectomy and stenting. *Am J Cardiol* 1994;74:748-54.
- Baumbach A, Bittl JA, Fleck E, et al. and the coinvestigators of the U.S. and European Percutaneous Excimer Laser Coronary Angioplasty (PELCA) Registries. Acute complications of excimer laser coronary angioplasty: a detailed analysis of multicenter results. *J Am Coll Cardiol* 1994;23:1305-13.
- Tcheng JE, Wells LD, Phillips HR, Deckelbaum LI, Golobic RA. Development of a new technique for reducing pressure pulse generation during excimer laser coronary angioplasty. *Cathet Cardiovasc Diagn* 1995;34:15-22.
- Baumbach A, Haase KK, Rose C, Oberhoff M, Hanke H, Karsch K. Formation of pressure waves during in vitro excimer laser irradiation in whole blood and the effect of dilution with contrast media and saline. *Laser Surg Med* 1994;14:3-6.
- Deckelbaum LI, Natarajan MK, Bittl JA, et al. Effect of intracoronary saline infusion on dissection during excimer laser coronary angioplasty: a randomized trial. *J Am Coll Cardiol* 1995;26:1264-9.
- Bittl J, Ryan TJ, Keaney JF, et al. for the Percutaneous Excimer Laser Coronary Angioplasty Registry. Coronary artery perforation during excimer laser coronary angioplasty. *J Am Coll Cardiol* 1993;21:1158-65.
- The EPILOG Investigators. Platelet glycoprotein IIb/IIIa receptor blockage and low-dose heparin during percutaneous coronary revascularization. *N Engl J Med* 1997;336:1689-96.
- Stone GW, De Marchena E, Dageforde D, et al. for the Laser Angioplasty Versus Angioplasty (LAVA) Trial Investigators. Prospective, randomized, multicenter comparison of laser-facilitated balloon angioplasty versus stand-alone balloon angioplasty in patients with obstructive coronary artery disease. *J Am Coll Cardiol* 1997;30:1714-21.
- Mehran R, Mintz GS, Satler LF, et al. Treatment of in-stent restenosis with excimer laser coronary angioplasty. *Circulation* 1997;96:2183-9.
- Köster R, Hamm CW, Terres W, et al. Treatment of in-stent coronary restenosis by excimer laser angioplasty. *Am J Cardiol* 1997;80:1424-8.