

Intravascular Ultrasound Findings in the Multicenter, Randomized, Double-Blind RAVEL (RAnдомized study with the sirolimus-eluting VELOCITY balloon-expandable stent in the treatment of patients with de novo native coronary artery Lesions) Trial

Patrick W. Serruys, MD, PhD; Muzaffer Degertekin, MD; Kengo Tanabe, MD; Alexandre Abizaid, MD; J. Edouardo Sousa, MD; Antonio Colombo, MD; Giulio Guagliumi, MD; William Wijns, MD, PhD; Wietze K. Lindeboom, MSc; Jurgen Ligthart, MSc; Pim J. de Feyter, MD, PhD; Marie-Claude Morice, MD; for the RAVEL Study Group

Background—The goal of this intravascular ultrasound investigation was to provide a more detailed morphological analysis of the local biological effects of the implantation of a sirolimus-eluting stent compared with an uncoated stent.

Methods and Results—In the RAVEL trial, 238 patients with single de novo lesions were randomized to receive either an 18-mm sirolimus-eluting stent (Bx VELOCITY stent, Cordis) or an uncoated stent (Bx VELOCITY stent). In a subset of 95 patients (sirolimus-eluting stent=48, uncoated stent=47), motorized intravascular ultrasound pullback (0.5 mm/s) was performed at a 6-month follow-up. Stent volumes, total vessel volumes, and plaque-behind-stent volumes were comparable. However, the difference in neointimal hyperplasia (2 ± 5 versus 37 ± 28 mm³) and percent of volume obstruction ($1\pm3\%$ versus $29\pm20\%$) at 6 months between the 2 groups was highly significant ($P<0.001$), emphasizing the nearly complete abolition of the proliferative process inside the drug-eluting stent. Analysis of the proximal and distal edge volumes showed no significant difference between the 2 groups in external elastic membrane or lumen and plaque volume at the proximal and distal edges. There was also no evidence of intrastent thrombosis or persisting dissection at the stent edges. Although there was a higher incidence of incomplete stent apposition in the sirolimus group compared with the uncoated stent group ($P<0.05$), it was not associated with any adverse clinical events at 1 year.

Conclusions—Sirolimus-eluting stents are effective in preventing neointimal hyperplasia without creating edge effect and without affecting the plaque burden behind the struts. (*Circulation*. 2002;106:798-803.)

Key Words: stents ■ restenosis ■ ultrasonics ■ drugs

The main limitation of the percutaneous techniques of revascularization remains the phenomenon of restenosis, which is an exaggerated healing response to the vessel wall injury that occurs as a result of mechanical dilatation. The 3 processes involved in restenosis are immediate elastic recoil, late constrictive remodeling, and neointimal hyperplasia. The scaffolding properties of a stent can control the first 2 processes but lead to an increase in neointimal hyperplasia.

Pilot studies testing the safety, feasibility, and efficacy of the sirolimus-eluting stent have demonstrated a near complete abolition of neointimal hyperplasia.^{1,2} These pilot studies have been conducted on patients with Benestent type lesions in large vessels, and the stents were implanted under intravascular ultrasound (IVUS) guidance.

The RAVEL trial is a multicenter randomized study involving patients with more complex lesions in smaller vessels in whom IVUS guidance was not used during stent implantation.³ In a subset of the enrolled patients, quantitative 3-dimensional IVUS assessment was performed at follow-up. The goal of this investigation was to provide a more detailed morphological analysis of the local biological effects of the implantation of a sirolimus-eluting stent.

Sirolimus has potent antiproliferative and antimigratory effects.⁴ Intravascular brachytherapy also has antiproliferative and antimigratory effects but has been associated with certain side effects, including edge restenosis,^{5,6} persisting dissection,^{7,8} increased plaque burden outside the struts of the stent with expansion of the external elastic membrane,^{8,9} late malapposition,¹⁰ late thrombotic occlusion,¹¹ and “black holes.”^{12,13}

Received March 4, 2002; revision received May 22, 2002; accepted May 23, 2002.

From the Thoraxcentre, Rotterdam, the Netherlands (P.W.S., M.D., K.T., J.L., P.d.F.); Institute Dante Pazzanese de Cardiologia, Sao Paulo, Brazil (A.A., J.E.S.); Centro Cuore Columbus, Milan, Italy (A.C.); Ospediali Riuniti di Bergamo, Bergamo, Italy (G.G.); Onze Lieve Vrouwe Ziekenhuis, Aalst, Belgium (W.W.); Cardialysis bv, Rotterdam, the Netherlands (W.K.L.); and Institut Cardiovasculaire Paris Sud, Massy, France (M.-C.M.).

Correspondence to Prof Patrick W. Serruys, Thoraxcentre, BD 404, Dr Molewaterplein 40, 3015 GD (PO Box 1738, 3000 DR), Rotterdam, The Netherlands. E-mail serruys@card.azr.nl

© 2002 American Heart Association, Inc.

Circulation is available at <http://www.circulationaha.org>

DOI: 10.1161/01.CIR.0000025585.63486.59

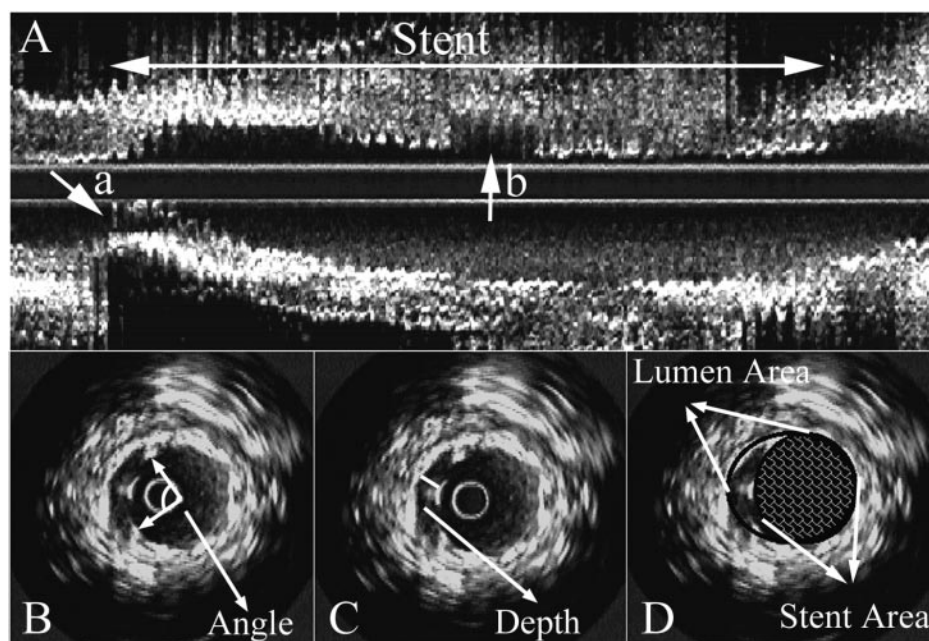


Figure 1. Methodology used to evaluate incomplete apposition at follow-up by IVUS. The figures illustrate the variety of measurements performed to quantify the incomplete apposition observed: location of incomplete apposition (arrows a and b) on a longitudinal view (A), circumferential extent in angular degree (B) maximal depth, distance between the vessel wall and the most incompletely apposed strut (C), and the area of incomplete apposition (lumen area–stent area=incomplete apposition area) in a single IVUS cross section (D).

On the basis of the previous experience with brachytherapy, we specifically looked for any evidence of these harmful effects in the patients enrolled in the RAVEL trial.

Methods

Patient Selection

The RAVEL trial enrolled 238 patients at 19 European and South American medical centers, and a subset of 95 patients enrolled at 6 centers underwent an IVUS investigation of their stents at 6 months. The study was reviewed and approved by each participating institution's Ethics Review Committee. All randomized patients signed a specific written informed consent mentioning the follow-up IVUS investigation. Patients were eligible if they had a diagnosis of stable or unstable angina pectoris or documented silent ischemia and if they had a single de novo target lesion of a native coronary artery in a vessel between 2.5 and 3.5 mm in diameter that could be covered by an 18-mm stent. Patients were not eligible for enrollment if they had an evolving myocardial infarction; an unprotected left main coronary artery stenosis $\geq 50\%$; an ostial target lesion; a calcified lesion that could not be successfully predilated; an angiographically visible thrombus within the target lesion; a left ventricular ejection fraction below 30%; or intolerance to aspirin, clopidogrel, or ticlopidine.

Study Procedures

After successful predilatation, patients were randomized 1:1 in a double-blind fashion to undergo the implantation of either an uncoated metal Bx VELOCITY Balloon-Expandable Stent or a sirolimus-eluting Bx VELOCITY Balloon-Expandable Stent (Cordis Corp, Johnson & Johnson). The sirolimus-eluting stents were indistinguishable from the uncoated metal stents to the naked eye. Postdilatation was performed as necessary to achieve a residual stenosis below 20% with a TIMI grade III flow. In case of dissection or of incomplete coverage of the lesion, additional study stents from the same randomization assignment were used as necessary.

Heparin was administered in intravenous boluses to maintain an activated clotting time >250 seconds for the duration of the procedure and was discontinued within 12 hours. Aspirin, at least 100 mg, was administered 12 hours before the procedure and continued indefinitely. A loading dose of 300 mg of clopidogrel was administered, preferably

48 hours before the procedure, followed by 75 mg once daily for 8 weeks. Alternatively, ticlopidine 250 mg twice daily was begun 1 day before the procedure and continued for 8 weeks.

Patient Follow-Up

At 30 days, 6 months, and 12 months, patients underwent evaluation of anginal status according to the Canadian Cardiovascular Society Classification of angina¹⁴ and the Braunwald Classification for unstable angina,¹⁵ as well as monitoring of major adverse cardiac events or additional revascularization of the index target lesion. A 12-lead ECG was performed at each visit; follow-up angiography and an IVUS investigation was performed at 180 ± 30 days.

Quantitative Coronary Angiography

Coronary angiograms were obtained in multiple views after patients had received an intracoronary injection of nitrates. Quantitative analyses of all pre-, peri-, and postprocedural angiographic data were performed by an independent core laboratory (Cardialysis, Rotterdam, the Netherlands) and analyzed quantitatively by edge-detection techniques.¹⁶ These data have been reported previously.

Quantitative Intravascular Ultrasound

At a 6-month follow-up, stented vessel segments were examined with mechanical IVUS (CardioVascular Imaging System, CVIS) using automated pullback at 0.5 mm per second. A coronary segment beginning 5 mm distal to and extending 5 mm proximal to the stented segment was also examined. A computer-based contour detection program was used for automated 3D reconstruction of the stented segment from up to 200 cross-sectional images. Lumen, stent boundaries, and external elastic membrane were detected using a minimum cost algorithm.^{17,18} Total vessel volume (TVV), stent volume (SV), and lumen volume (LV) were calculated as $V = \sum_{i=1}^n A_i \cdot H$, where V is volume, A is total vessel, stent, or lumen area (as desired) in a given cross-sectional image, H is thickness of the coronary artery slice, and n is the number of slices. Lumen volume did not include the incomplete apposition spaces, and in absence of neointimal hyperplasia, lumen volume was delineated by the boundaries of the struts. Total plaque volume (TPV), plaque volume behind the stent (PBS), and neointimal hyperplasia (NIH) were calculated as $TVV - LV$, $TVV - SV$, and $SV - LV$, respectively. Percentage of

TABLE 1. Comparison of Baseline Demographic and Angiographic Data of the Population Undergoing IVUS Investigation at Follow-Up With the Entire Cohort of Randomized Patients

	Sirolimus-Coated Stent (n=48)	Uncoated Stent (n=47)	All Randomized (n=238)
Age, y	62.2±10.7	58.4±9.7	60.7±10.4
Men	72.9	85.1	75.6
Diabetes mellitus	14.6	14.9	18.5
Hypercholesterolemia	45.8	52.2	51.5
Hypertension	45.8	53.3	49.2
Previous MI	41.7	27.7	35.7
Previous CABG	2.1	2.1	1.7
Previous PTCA	18.8	8.5	18.1
Current smoker	31.3	40.4	29.8
Unstable angina	58.6	57.4	50.2
Stable angina	32.6	31.9	38.7
Silent ischemia	8.7	10.6	11.1
RVD before procedure, mm	2.59±0.61	2.66±0.55	2.62±0.53
DS after procedure, %	65±10	62±9	64±10
MLD before procedure, %	0.90±0.29	1.01±0.38	0.95±0.33
RCA/LAD/CX, %	22.9/54.2/22.9	23.9/52.2/23.9	26.8/49.8/23.4

Values are given as mean±SD or percentage.

The difference between demographics and angiographic preprocedure measurements was tested by Fisher's exact and unpaired *t* tests (*P*=NS). MI indicates myocardial infarction; CABG, coronary artery bypass graft; PTCA, percutaneous transluminal coronary angioplasty; RVD, reference vessel diameter; DS, diameter stenosis; and MLD, minimal luminal diameter.

obstruction volume was calculated as neointimal volume/stent volume × 100 at the 6-month follow-up. For the segments proximal and distal to the stent, the vessel volume was measured at each cross section as the area lying within the external elastic lamina.

Feasibility, reproducibility and inter- and intra-observer variability of this system have been validated in vitro and in vivo.^{17,18} The quantitative ultrasound analyses were performed by an independent core laboratory (Cardialysis BV, Rotterdam, the Netherlands).

Qualitative IVUS parameters assessed in the study included persisting edge tears and incomplete stent apposition. Edge tears were defined as disruption of plaque immediately adjacent to the stent ends, where the flap could be clearly differentiated from the underlying plaque. Incomplete stent apposition was defined as 1 or more struts clearly separated from vessel wall with evidence of blood speckles behind the strut,^{19,20} and because it was based on the consensus of 3 independent analysts, the determination was blind for the type of stent used. The measures of agreement by Kappa analysis between 3 observers were 0.87, 0.85 and 0.80, respectively (*P*=NS).

The number of loci exhibiting areas of incomplete stent apposition per stent was determined by cross-sectional IVUS images. The total length of these single or multiple areas of incomplete apposition were calculated from the number of frames involved. The maximal number of struts separated from the vessel wall on 1 single cross section, as well as the maximal depth (distance between the most incompletely apposed strut and the vessel wall) and the maximal circumferential extent of incomplete apposition (expressed in angular degrees) are reported. Finally, the volume of the incompletely apposed segments was quantified in mm³ and related to the stent volume-in percent (Figure 1).

End Points

The primary end point of the study is angiographic in-stent late loss at a 6-month follow-up as determined by quantitative coronary angiography. The secondary clinical end point of the study was a composite of major adverse cardiac events, including cardiac and noncardiac death, Q-wave and non-Q-wave myocardial infarctions, coronary artery by-

pass grafts, or target lesion or vessel revascularizations at 30 days, 6 months, and 12 months after the index procedure.³

Statistical Analysis

All analyses were performed on an intention-to-treat basis. Treatment group differences were tested by ANOVA or Wilcoxon rank sums scores for continuous variables. Discrete variables were described by counts and percentages and tested with Fisher's exact test.

The differences in event-free survival were compared by log-rank tests. A 2-sided *P* value <0.05 was considered statistically significant. To identify potential causative factors responsible for incomplete apposition, a multivariate analysis was performed including all the conventional pre-, peri-, and postprocedural factors recorded in the frame of this trial.

Results

The baseline demographic and angiographic data of this subset of patients were similar to those observed in the entire cohort of the patients randomized in the RAVEL trial, and the IVUS population was not the result of a biased selection of patients (Table 1).

Follow-up IVUS was obtained in 80% (95 of 118) of the eligible patients. The analysis of the 2 groups within the IVUS population shows that the stent volumes were comparable. At follow-up, there was no difference in the TVV or PBS volume, suggesting that the eluted drug did not affect the plaque burden located outside the stent structure (Table 2).

The differences in neointimal hyperplasia and percent of volume obstruction between the 2 groups were highly significant, emphasizing the near complete abolition of the proliferative process inside the stent (Figure 2).

The analysis of the proximal and distal edge volumes showed no significant difference in EEM, lumen, and plaque volume at the proximal and distal edges (Table 2).

TABLE 2. IVUS Measurements at 6-Month Follow-Up

Lesion Parameters Measured	Sirolimus-Eluting Stent (n=48)			Uncoated Stent (n=47)		
	Proximal	Stent	Distal	Proximal	Stent	Distal
Total vessel volume	64±27	280±69	51±24	59±24*	280±75*	49±21*
Plaque and NIH	31±15	152±47	21±12	30±13*	183±53†	24±14*
Plaque behind stent	NA	150±44	NA	NA	146±43*	NA
Stent volume	NA	131±35	NA	NA	132±36*	NA
Neointimal volume	NA	2±5	NA	NA	37±28‡	NA
Lumen volume	33±16	129±34	30±14	30±15*	95±41‡	25±11*
% Stent volume obstruction	NA	1±3	NA	NA	29±20‡	NA

*Not significant; † $P<0.05$; ‡ $P<0.001$.

NA indicates not applicable.

Qualitative assessment by IVUS did not reveal any evidence of intrastent thrombosis or persisting dissection at the stent edges, but showed a 21% incidence of incomplete apposition in the sirolimus group compared with a 4% incidence in the uncoated stent group. Table 3 provides a quantitative evaluation of the extent of incomplete apposition by the number of individual segments that were incompletely apposed, as well as their total length, maximal depth, circumferential extent, and volume of incomplete apposition. There was no significant difference between the 2 groups other than the frequency of the occurrence of this finding (21% versus 4%).

Correlation Between Quantitative Coronary Angiography and Incomplete Apposition Detected by IVUS

The binary restenosis rate and the late angiographic loss in the sirolimus group followed up with IVUS were 0% and 0.06 ± 0.30 mm, respectively, whereas the restenosis rate and the late loss in the uncoated stent group were 23.4% and 0.91 ± 0.58 mm.

The quantitative coronary angiography analysis of the 48 patients who received a sirolimus-eluting stent showed that the mean diameter of the stent segment remained unchanged 2.87 ± 0.46 versus 2.87 ± 0.49 , whereas the mean diameter of the 47 patients treated with an uncoated stent decreased significantly from 2.90 ± 0.42 to 2.17 ± 0.48 ($P<0.001$). The mean diameter of the stents in the 10 patients who received a sirolimus-eluting stent and had incomplete apposition at follow-up was on average 3.16 ± 0.57 mm and was significantly larger than the mean diameter of the stents of the 38 patients who had their stents well apposed at follow-up (2.79 ± 0.43 mm, $P<0.05$). Incomplete apposition was more likely to occur in larger vessels. Stent diameter, however, was not used in the multivariate analysis of incomplete apposition.

Clinical Events at 1-Year Follow-Up

In the subset of patients (n=95) investigated with IVUS, the event-free survival rates at 1 year (98% in the sirolimus group versus 72% in the uncoated stent group, $P<0.001$) are very similar to the rates observed for the entire cohort of randomized patients (94% in the sirolimus group versus 72% in the uncoated stent group, $P<0.0001$). The 10 patients with incomplete stent apposition in the sirolimus group were asymptomatic and event-free at 1 year, whereas 1 of the 2

patients with incomplete apposition in the placebo group underwent percutaneous target lesion revascularization.

Discussion

The present results confirm the volumetric ultrasound analysis performed in the First In Man (FIM) trial at 4, 6, and 12 months.^{1,2} The percent of stent volume obstruction and the volume of neointimal hyperplasia in the sirolimus group are comparable to those observed in the FIM trial and are markedly different from those measured in the control group of the RAVEL trial. The cumulative frequency curve of the NIH shows that almost 75% of the stented segments do not exhibit NIH, and the term naked struts has been coined to describe the IVUS appearance of the sirolimus-eluting stent struts. It should be emphasized that the axial resolution of IVUS is in the range of 150 to 200 μ m and does not permit any assessment of the reendothelialization. The volume of PBS and the total vessel volume at follow-up were similar in both groups, suggesting that no significant plaque shrinking or positive/negative remodeling occurred as a result of sirolimus elution. This contrasts with what has been seen with intravascular brachytherapy, where both positive remodeling of the vessel and plaque progression have been reported after a 6 to 8-month follow-up.^{8,9}

The quantitative and qualitative assessments in this trial have demonstrated the absence of an edge effect in drug-eluting stents when compared with the placebo, the absence of persisting intimal tears at the stent edges, and the absence of parietal thrombi or "black holes" inside the stent.

Because of the initial report that there were more cases of late incomplete apposition detected by IVUS in the sirolimus group, this observation has created a great deal of interest. It therefore seemed important to evaluate this phenomenon carefully to determine whether there were any clinical sequelae to put it in the proper perspective. Because IVUS assessment of the completeness of apposition immediately after deployment was not performed, it is not possible to determine whether these few cases of incomplete apposition observed at follow-up are the result of late acquired malapposition or the consequence of an acute incomplete deployment. Therefore, we have used the broader term "incomplete apposition." The completeness of apposition may be highly dependent on the presence or absence of intravascular guidance at the time of deployment; in the FIM trial, performed with IVUS guidance, only 2 cases of late

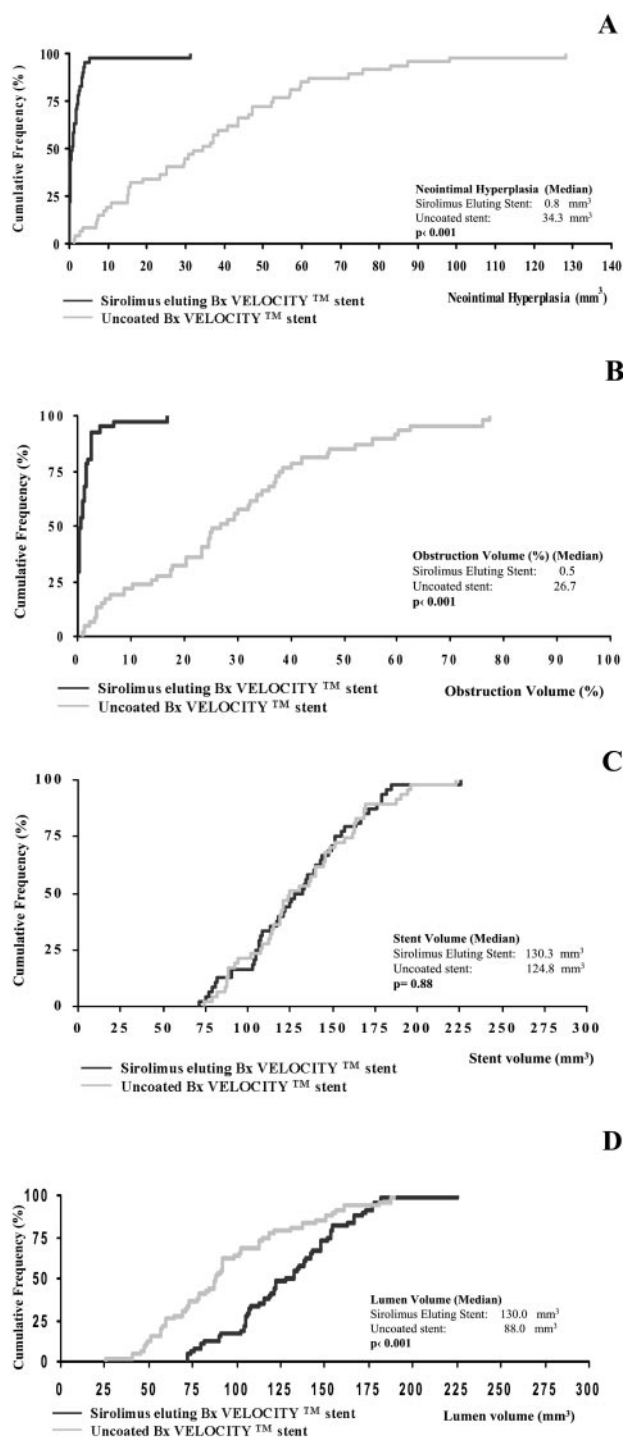


Figure 2. Cumulative distribution curve of in-stent neointimal hyperplasia volume at follow-up (A), percent obstruction volume of the stent at follow-up (B), stent volume at follow-up (C), and in-stent lumen volume at follow-up (D) for the 48 patients treated with sirolimus-eluting stent (black lines) and the 47 placebo patients treated with an uncoated Bx VELOCITY stent (gray line). Although stent volume after the procedure is similar, the neointimal and percent of obstruction volume curves are significantly shifted to the left for the sirolimus group.

acquired malapposition at follow-up were recorded out of 45 patients enrolled in this pilot study. A 17% incidence of acute incomplete apposition has been reported in a recent series of 62

patients in which bare metal stent deployment, judged optimal by angiography, was systematically evaluated by IVUS. In the IVUS-guided trials Stent Treatment Region assessed by Ultrasound Tomography (STRUT) and Angiography-directed Versus IVUS-Directed coronary stent placement trial (AVID), the incidences of malapposition are 22% and 13%, respectively.^{20,21} Although the observed frequency of 21% in the sirolimus group is not very different from those reported with bare stents, it does not explain the difference seen between the 2 randomized groups in RAVEL.

Several purely speculative hypotheses may be raised to explain this general phenomenon. The first is that the antiproliferative action of the drug may preclude the growth of tissue in the void between struts and the vessel wall initially created by an incomplete deployment. The observation that larger vessels were more likely to exhibit this phenomenon seems to support this hypothesis. Second, the antimetabolite effect of the drug may induce phenomena such as necrosis or apoptosis, which may generate a new empty space between the struts and the vessel wall, which were originally in close contact. Third, the antimigratory and antiproliferative mechanism of action may prevent myoblasts from colonizing and proliferating in an organized thrombus (for example, in an unstable patient), which will dissolve at follow-up, creating a new empty space. A multivariate analysis considering conventional pre-, peri-, and postprocedural factors recorded in this trial did not identify any causative factors other than a large minimum luminal diameter after the procedure, elution of sirolimus, and absence of diabetes as predictors of incomplete apposition. The more proliferative nature of the healing process in the diabetic patients, although adequately inhibited by sirolimus (late loss 0.08 mm in diabetics), may be sufficient to fill in the gap between the sirolimus-eluting stents and the vessel wall when stents are initially incompletely deployed. This may explain why this finding was not present in any of the diabetics in this study.

Similar observations will undoubtedly be made with stents that elute drugs other than sirolimus. Serial IVUS observations from the first human experience with the QP₂-eluting polymer stent system have indicated that mild incomplete stent apposition and persistent edge tears were observed in 5% and 10%, respectively, of the 20 cases studied in this registry,¹⁹ despite the fact that the dose of taxane analogue used in this registry seems to possess less potent antimigratory and antiproliferative properties than sirolimus (mean neointimal area of 1.16 ± 1.35 mm² versus of 0.09 ± 0.26 mm² in the present study). The angiographic late loss results reported for TAXUS I (a Feasibility Study Evaluating Safety of the NIRx Paclitaxel-Coated Conformer Coronary Stent for the Treatment of De Novo Coronary Lesions) (0.35 ± 0.47 mm), the ASian Paclitaxel-Eluting stent Clinical Trial (ASPECT) study highest dose (0.29 ± 0.72 mm) and European Evaluation of Paclitaxel-Eluting Stents (ELUTES) highest dose (0.10 ± 0.68 mm), when the range of standard deviation is factored in, suggest the occurrence of negative late loss (or late gain) compatible with late malapposition in some patients, while at the same time suggesting in other patients substantially more neointimal hyperplasia than observed in the present study. The clinical significance of these observations in these trials remains to be determined.

It is of paramount importance to emphasize that in the sirolimus group, the incomplete apposition detected in some patients at 6 months did not translate into any subacute or late (1 year) clinical events. Furthermore, late (18-, 24-, and 36-month)

TABLE 3. Characteristics and Quantification of Incomplete Apposition of Stent

	Sirolimus-Eluting Stent	Uncoated Stent	P
Frequency per patient (%)	10/48 (21)	2/47 (4)	0.001
Frequency of incomplete stent apposition as a function of nominal stent size (patients can have more than 1 stent)			
2.5 mm	1/10 (10)	0/3 (0)	NS
3.0 mm	4/27 (15)	3/36 (8)	NS
3.5 mm	5/13 (38)	0/9 (0)	NS
Number of sites per stent exhibiting incomplete apposition	1.9 (1–3)	2 (2–2)	NS
Localization of incomplete apposition sites			
Proximal edge of the stent, %	5/19 (27)	1/4 (25)	NS
Middle part of the stent, %	12/19 (63)	3/4 (75)	NS
Distal edge of the stent, %	2/19 (10)	0/4 (0)	NS
Maximal number of struts separated from vessel wall on one single cross-section	3.6 (2–5)	4.0 (3–5)	NS
Total length on one single or multiple longitudinal views, mm	6.7 (3.5–13.5)	6.9 (5.3–8.4)	NS
Maximal depth, mm	0.75 (0.3–1.2)	0.62 (0.6–0.7)	NS
Maximal circumferential extent, arc°	154° (63–270)	131° (104–158)	NS
Volume per stent, mm ³	20 (3–66)	27 (16–39)	NS
Volume per stent volume, %	14 (2–42)	14 (7–20)	NS

Values are mean (%) or mean (range).

NS indicates not significant.

IVUS investigation of cases of malapposition after brachytherapy has shown that this phenomenon may disappear at follow-up (unpublished data, personal communication of J. Ligthart, MSc, January, 2002). Therefore, the significance of this phenomenon may be trivial and clinically irrelevant, but longer-term follow-up will be necessary to answer this question definitively.

Acknowledgments

This study was supported by a grant from Cordis Corporation, a Johnson & Johnson Company. We appreciate the constructive suggestions and assistance of Dr Brian Firth in reviewing this manuscript.

References

- Rensing B, Vos J, Smits P, et al. Coronary restenosis elimination with a sirolimus eluting stent: first European human experience with six month angiographic and intravascular ultrasonic follow-up. *Eur Heart J*. 2001; 22:2125–2130.
- Sousa JE, Costa MA, Abizaid AC, et al. Sustained suppression of neo-intimal proliferation by sirolimus-eluting stents: one-year angiographic and intravascular ultrasound follow-up. *Circulation*. 2001;104:2007–2011.
- Morice MC, Serruys PW, Sousa JE, et al. A randomized comparison of a sirolimus-eluting stent with a standard stent for coronary revascularization. The RAVEL trial. *N Engl J Med*. 2002;346:1773–1780.
- Marx SO, Marks AR. Bench to bedside: the development of rapamycin and its application to stent restenosis. *Circulation*. 2001;104:852–855.
- Albiero R, Nishida T, Adamian M, et al. Edge restenosis after implantation of high activity (32P) radioactive beta-emitting stents. *Circulation*. 2000;101:2454–2457.
- Wardeh AJ, Knook AH, Kay IP, et al. Clinical and angiographical follow-up after implantation of a 6–12 micro Ci radioactive stent in patients with coronary artery disease. *Eur Heart J*. 2001;22:669–675.
- Kay IP, Sabate M, Van Langenhove G, et al. Outcome from balloon induced coronary artery dissection after intracoronary beta radiation. *Heart*. 2000;83:332–337.
- Kay IP, Sabate M, Costa MA, et al. Positive geometric vascular remodeling is seen after catheter-based radiation followed by conventional stent implantation but not after radioactive stent implantation. *Circulation*. 2000;102:1434–1439.
- Sabate M, Serruys PW, van der Giessen WJ, et al. Geometric vascular remodeling after balloon angioplasty and beta- radiation therapy: a three-dimensional intravascular ultrasound study. *Circulation*. 1999;100:1182–1188.
- Kozuma K, Costa MA, Sabate M, et al. Late stent malapposition occurring after intracoronary beta-irradiation detected by intravascular ultrasound. *J Invas Cardiol*. 1999;11:651–655.
- Costa MA, Sabate M, van der Giessen WJ, et al. Late coronary occlusion after intracoronary brachytherapy. *Circulation*. 1999;100:789–792.
- Castagna MT, Mintz GS, Weissman N, et al. “Black hole”: echolucent restenotic tissue after brachytherapy. *Circulation*. 2001;103:778.
- Kay IP, Wardeh AJ, Kozuma K, et al. The pattern of restenosis and vascular remodeling after cold-end radioactive stent implantation. *Eur Heart J*. 2001;22:1311–1317.
- Campeau L. Grading for angina pectoris. *Circulation*. 1976;54:522–523.
- Braunwald E. Unstable angina: a classification. *Circulation*. 1989;80:410–414.
- Serruys PW, Foley DP, de Feyter PJ, eds. *Quantitative Coronary Angiography in Clinical Practice*. Dordrecht, the Netherlands: Kluwer Academic Publishers; 1994.
- Li W, von Birgelen C, Hartlooper A, et al. Semi-automated contour detection for volumetric quantification of intracoronary ultrasound. In: *Computers in Cardiology*. Washington, DC: IEEE Computer Society Press; 1994:277–280.
- Von Birgelen C, di Mario C, Li W, et al. Morphometric analysis in three-dimensional intracoronary ultrasound an in vivo and in vitro study performed with a novel system for contour detection of lumen and plaque. *Am Heart J*. 1996;132:516–527.
- Honda Y, Grube E, de la Fuente L, et al. Novel drug-delivery stent: intravascular ultrasound observations from the first human experience with the QP2-eluting polymer stent system. *Circulation*. 2001;104:380–383.
- Kobayashi Y, Honda Y, Christie LG, et al. Long-term vessel response to a self-expanding coronary stent: a serial volumetric intravascular ultrasound analysis from the ASSURE trial. *J Am Coll Cardiol*. 2001;37:1329–1334.
- Uren NG, Schwarzacher SP, Metz JA, et al. Predictors and outcomes of stent thrombosis: an intravascular ultrasound registry. *Eur Heart J*. 2002;23: 124–132.