

The New England Journal of Medicine

Copyright © 2002 by the Massachusetts Medical Society

VOLUME 346

JUNE 6, 2002

NUMBER 23



A RANDOMIZED COMPARISON OF A SIROLIMUS-ELUTING STENT WITH A STANDARD STENT FOR CORONARY REVASCULARIZATION

MARIE-CLAUDE MORICE, M.D., PATRICK W. SERRUYS, M.D., PH.D., J. EDUARDO SOUSA, M.D., JEAN FAJADET, M.D.,
ERNESTO BAN HAYASHI, M.D., MARCO PERIN, M.D., ANTONIO COLOMBO, M.D., G. SCHULER, M.D., PAUL BARRAGAN, M.D.,
GIULIO GUAGLIUMI, M.D., FERENC MOLNÁR, M.D., AND ROBERT FALOTICO, PH.D., FOR THE RAVEL STUDY GROUP*

ABSTRACT

Background The need for repeated treatment of restenosis of a treated vessel remains the main limitation of percutaneous coronary revascularization. Because sirolimus (rapamycin) inhibits the proliferation of lymphocytes and smooth-muscle cells, we compared a sirolimus-eluting stent with a standard uncoated stent in patients with angina pectoris.

Methods We performed a randomized, double-blind trial to compare the two types of stents for revascularization of single, primary lesions in native coronary arteries. The trial included 238 patients at 19 medical centers. The primary end point was in-stent late luminal loss (the difference between the minimal luminal diameter immediately after the procedure and the diameter at six months). Secondary end points included the percentage of in-stent stenosis of the luminal diameter and the rate of restenosis (luminal narrowing of 50 percent or more). We also analyzed a composite clinical end point consisting of death, myocardial infarction, and percutaneous or surgical revascularization at 1, 6, and 12 months.

Results At six months, the degree of neointimal proliferation, manifested as the mean (\pm SD) late luminal loss, was significantly lower in the sirolimus-stent group (-0.01 ± 0.33 mm) than in the standard-stent group (0.80 ± 0.53 mm, $P < 0.001$). None of the patients in the sirolimus-stent group, as compared with 26.6 percent of those in the standard-stent group, had restenosis of 50 percent or more of the luminal diameter ($P < 0.001$). There were no episodes of stent thrombosis. During a follow-up period of up to one year, the overall rate of major cardiac events was 5.8 percent in the sirolimus-stent group and 28.8 percent in the standard-stent group ($P < 0.001$). The difference was due entirely to a higher rate of revascularization of the target vessel in the standard-stent group.

Conclusions As compared with a standard coronary stent, a sirolimus-eluting stent shows considerable promise for the prevention of neointimal proliferation, restenosis, and associated clinical events. (N Engl J Med 2002;346:1773-80.)

Copyright © 2002 Massachusetts Medical Society.

THE growing use of stents has improved the results of percutaneous coronary revascularization.¹⁻⁵ However, in-stent restenosis continues to limit the long-term success of this approach.^{6,7} For example, in a recent randomized comparison of coronary-artery bypass surgery and stenting in patients with multivessel disease, additional revascularization procedures were performed within one year in 21.0 percent of patients who had undergone stenting, as compared with 3.8 percent of patients treated surgically.⁸

In controlled trials, several pharmaceutical agents have failed to inhibit restenosis after coronary interventions.⁹ In contrast, the systemic and local delivery of sirolimus (rapamycin), a macrocyclic lactone that inhibits cytokine-mediated and growth-factor-mediated proliferation of lymphocytes and smooth-muscle cells, reduced neointimal proliferation in studies in animals and in a small clinical study.¹⁰⁻¹² We conducted a study to compare the performance of a coronary stent that slowly releases sirolimus over a period of 30 days with that of a standard uncoated stent.

METHODS

Selection of Patients

The study was a randomized, double-blind trial performed at 19 medical centers (listed in the Appendix). It was approved by

From Institut Cardiovasculaire Paris Sud, Massy, France (M.-C.M.); Thoraxcentrum, Rotterdam, the Netherlands (P.W.S.); Instituto Dante Pazzanese de Cardiologia, São Paulo, Brazil (J.E.S.); Clinique Pasteur, Toulouse, France (J.E.); Instituto Nacional de Cardiologia Ignacio Chavez, Mexico City, Mexico (E.B.H.); the Heart Institute of the University of São Paulo, São Paulo, Brazil (M.P.); Centro Cuore Columbus, Milan, Italy (A.C.); Herzzentrum, Leipzig, Germany (G.S.); Centre Hospitalier Privé Beaugregard, Marseilles, France (P.B.); Azienda Ospedaliera Ospedali Riuniti di Bergamo, Bergamo, Italy (G.G.); Semmelweis Egyetem Egészségtudományi Kar, Budapest, Hungary (F.M.); and Cordis, Johnson & Johnson, Warren, N.J. (R.E.). Address reprint requests to Dr. Morice at the Institut Hospitalier Jacques Cartier, Ave. du Noyer Lambert, 91300 Massy, France.

*The members of the RAVEL (Randomized Study with the Sirolimus-Coated Bx Velocity Balloon-Expandable Stent in the Treatment of Patients with de Novo Native Coronary Artery Lesions) study group are listed in the Appendix.

the ethics committee at each participating institution, and all patients gave written informed consent. The study was conducted from August 2000 to August 2001.

Patients were eligible for the study if they were 18 to 85 years old, were not pregnant and were protected against pregnancy during the study, and had received a diagnosis of stable or unstable angina or silent ischemia. Additional eligibility criteria were the presence of a single primary target lesion in a native coronary artery that was 2.5 to 3.5 mm in diameter and that could be covered by an 18-mm stent; stenosis of 51 to 99 percent of the luminal diameter, as estimated visually; and a flow rate of grade 1 or higher according to the classification of the Thrombolysis in Myocardial Infarction (TIMI) trial. Patients were not eligible for enrollment if they had an evolving myocardial infarction, stenosis of the left-main coronary artery, unprotected by a graft, that caused luminal narrowing of 50 percent or more, an ostial lesion, a calcified lesion that could not be completely dilated before stenting, an angiographically visible thrombus within the target lesion, a left ventricular ejection fraction of less than 30 percent, or an intolerance of aspirin, clopidogrel, ticlopidine, heparin, stainless steel, or contrast material.

The Sirolimus-Eluting Stent

Sirolimus was blended in a mixture of nonerodable polymers, and a layer of sirolimus-polymer matrix with a thickness of 5 μm was applied to the surface of a stainless-steel, balloon-expandable stent (Bx Velocity, Cordis, Johnson & Johnson). The stent was loaded with a fixed amount of sirolimus per unit of metal surface area (140 μg of sirolimus per square centimeter). A layer of drug-free polymer was applied on top of the drug-polymer matrix as a diffusion barrier to prolong the release of the drug. The stent was designed to release approximately 80 percent of the drug within 30 days after implantation.

Study Procedures

Codes for random assignments to the treatment groups were generated by computer in blocks of four and were distributed in sealed envelopes to each participating center. Patients were randomly assigned to the groups in a 1:1 ratio.

Lesions were treated with the use of standard interventional techniques. Stenting without predilation was prohibited. After successful predilation, patients were randomly assigned in a double-blind fashion to receive a standard uncoated stent or a sirolimus-eluting stent mounted on a rapid-exchange delivery system and inflated to 10 to 16 atm. The sirolimus-eluting stents were indistinguishable, except under a microscope, from the uncoated stents. After the stent had been implanted, further dilation was performed as necessary to ensure that there was less than 20 percent residual stenosis, with a TIMI grade III flow rate. In case of dissection or incomplete coverage of the lesion, additional stents of the same type as the assigned stent (coated or uncoated) were used.

Intravenous boluses of heparin were administered to maintain an activated clotting time that exceeded 250 seconds during the procedure and were discontinued within 12 hours. Treatment with aspirin, at a dose of at least 100 mg per day, was begun 12 hours before the procedure and continued indefinitely. A loading dose of 300 mg of clopidogrel was administered 48 hours before the procedure, followed by 75 mg daily for eight weeks. Alternatively, treatment with ticlopidine, at a dose of 250 mg twice daily, was begun one day before the procedure and continued for eight weeks. A successful procedure was defined as the successful implantation of the study device, with stenosis of less than 20 percent of the vessel diameter and no major cardiac events during the hospital stay.

Follow-up

Patients were evaluated at 30 days and at 6 and 12 months. They were asked specific questions about the interim develop-

ment of angina, according to the Canadian Cardiovascular Society classification of stable angina¹³ and the Braunwald classification of unstable angina.¹⁴ The patients were also monitored for major cardiac events and for the need for additional revascularization of the index target lesion. An electrocardiogram was obtained at each visit, and an angiographic study was performed at a mean (\pm SD) of 180 ± 30 days. Other studies and tests were performed at the discretion of the investigators at the participating centers. Because of the double-blind nature of the study, the decision to perform further revascularization of the target lesion or vessel after the six-month angiographic study was also left to the investigators' discretion.

Quantitative Coronary Angiographic Evaluation

Coronary angiograms were obtained in multiple views after the intracoronary injection of nitrates. Quantitative analyses of all angiographic data before, during, and after the procedure were performed by an independent core laboratory (Cardialysis, Rotterdam, the Netherlands) with the use of edge-detection techniques. The luminal diameter of the coronary artery and the degree of stenosis were measured before dilation, at the end of the procedure, and at six months. Restenosis was defined as stenosis of 50 percent or more of the luminal diameter. Late luminal loss was defined as the difference between the minimal luminal diameter immediately after the procedure and the diameter at six months. The target lesion was defined as the stented segment plus the 5-mm segments proximal and distal to the stented segment.

Intravascular Ultrasound Substudy

At the six-month visit, intravascular ultrasound examinations were performed by six centers in subgroups of 48 patients who had received a sirolimus-eluting stent and 47 who had received an uncoated stent.

Study End Points

The primary angiographic end point was in-stent luminal late loss, as determined by quantitative angiography. Secondary end points included the percentage of in-stent stenosis of the luminal diameter, the rate of restenosis (luminal narrowing of 50 percent or more), and the minimal luminal diameter of the stented segment and of the 5-mm segments proximal and distal to the stent at six months.

The primary clinical end point of the study was a composite of major cardiac events, including death, Q-wave or non-Q-wave myocardial infarction, coronary-artery bypass grafting, and revascularization of the target lesion or vessel 30 days, 6 months, and 12 months after the index procedure. A non-Q-wave myocardial infarction was defined by an increase in the creatine kinase level to more than twice the upper limit of the normal range, accompanied by an increased level of creatine kinase MB, in the absence of new Q waves on the surface electrocardiogram.

The end points were adjudicated by an independent clinical-events committee. In addition, a data and safety monitoring board that was not affiliated with the study sponsor reviewed the data to identify any safety issues related to the conduct of the study.

Statistical Analysis

We calculated that with a sample of 207 patients, the study would have 90 percent power to detect a difference in the mean late luminal loss of 0.25 mm between the two groups, assuming a standard deviation of 0.55 mm in each group, with the use of a two-group t-test and a two-sided significance level of 0.05.

All analyses were based on the intention-to-treat principle. For continuous variables, differences between the treatment groups were evaluated by analysis of variance or Wilcoxon's rank-sum test. For discrete variables, differences were expressed as counts and percentages and were analyzed with Fisher's exact test.

Revascularization of the target lesion or vessel and the composite of major adverse events during follow-up were analyzed by the

Kaplan–Meier method. Differences between the event-free survival curves for the two groups were compared with the use of the Wilcoxon and log-rank tests.

All listed authors participated in the study design, enrollment of patients, and data interpretation. The data were held by the core laboratory (Cardialysis, Rotterdam, the Netherlands), but all investigators had full access to them.

RESULTS

Characteristics of the Patients

Between August 2000 and January 2001, 120 patients were randomly assigned to receive the sirolimus-eluting stent, and 118 were assigned to receive the standard stent. With the exception of a significantly higher percentage of men in the standard-stent group, the two groups were similar with respect to all variables examined (Table 1). Overall, 76 percent of the patients were men, and the mean age was 60.7 years, with the expected prevalences of dyslipidemia, diabetes, hypertension, and current tobacco use. Stenting was performed because of unstable angina in 50 percent of the patients. The target vessel was the left

anterior descending coronary artery in 50 percent of the patients, the right coronary vessel in 27 percent, and the left circumflex artery in 23 percent. Nearly all the treated lesions were class B1 or B2 according to the American College of Cardiology–American Heart Association classification. Although all the target index lesions were primary lesions, 1.7 percent of the patients had undergone previous coronary-artery surgery and 18.1 percent had undergone previous percutaneous interventions for the treatment of other lesions.

Procedural Characteristics

The lesions in the two groups were treated similarly with the use of conventional techniques. Platelet glycoprotein IIb/IIIa inhibitors, the use of which was left to the discretion of the investigators at the participating centers, were administered to 10.1 percent of the patients in the sirolimus-stent group and 9.5 percent of those in the standard-stent group. The two groups did not differ significantly with respect to the

TABLE 1. BASE-LINE CHARACTERISTICS OF THE OVERALL PATIENT POPULATION AND OF EACH TREATMENT GROUP.*

CHARACTERISTIC	ALL PATIENTS (N=238)	SIROLIMUS STENT (N=120)	STANDARD STENT (N=118)
Age (yr)	60.7±10.4	61.8±10.7	59.7±10.1
Male sex (%)	76	70	81
Previous myocardial infarction (%)	36	38	34
Diabetes mellitus (%)	19	16	21
Treated hypercholesterolemia (%)	40	38	43
Treated hypertension (%)	61	62	61
Current smoker (%)	30	27	33
Angina pectoris (%)†			
Unstable	50	48	52
Stable	39	41	37
Silent ischemia (%)	11	11	11
Target coronary artery (%)‡			
LAD	50	49	51
RCA	27	27	27
LCX	23	24	22
Lesion type (%)§			
A	6	8	4
B1	37	38	35
B2	57	54	61
Reference diameter of the vessel (mm)	2.62±0.53	2.60±0.54	2.64±0.52
Length of lesion (mm)	9.58±3.25	9.56±3.33	9.61±3.18

*Plus–minus values are means ±SD. There were no significant differences between the treatment groups except for male sex (P=0.05).

†Unstable angina was defined according to the Braunwald classification,¹⁴ and stable angina according to the classification of the Canadian Cardiovascular Society.¹³

‡LAD denotes left anterior descending coronary artery, RCA right coronary artery, and LCX left circumflex artery.

§The classification of the American College of Cardiology–American Heart Association was used.

rate of successful stent placement (96.6 percent in the sirolimus-stent group and 93.1 percent in the standard-stent group).

Quantitative Angiographic Analysis

Angiographic data at six months were available for 211 of the 238 patients (88.7 percent). The mean reference diameter of the target vessel and the mean length of the lesion at base line were similar in the two groups (Table 1). The mean minimal luminal diameter of the stented segment and the length of the lesion before and after the procedure, as well as the reduction in stenosis immediately after the procedure, were also similar in the two groups (Table 2). At six months, however, the mean minimal luminal diameter of the stented segment was significantly greater in the sirolimus-stent group. The mean in-stent late loss, percentage of stenosis, and percentage of patients with 50 percent or more stenosis were -0.01 mm, 14.7 percent, and 0 percent, respectively, in the sirolimus-stent group, as compared with 0.80 mm, 36.7 percent, and 26.6 percent, respectively, in the standard-stent group ($P<0.001$ for each comparison). Figure 1 shows the cumulative frequency of stenosis immediately after the index procedure and at six months in each treatment group. Table 2 shows the results of subsegmental quantitative angiographic analyses. The late luminal loss at both the proximal and the distal edges of the stent was significantly less in the sirolimus-stent group than in the standard-stent group ($P<0.001$ for both comparisons). There

was a small degree of restenosis at the edges of the standard stent that was not present with the sirolimus-eluting stent.

In the subgroup of patients with diabetes, 19 patients received sirolimus-eluting stents, and 25 received standard stents. The minimal luminal diameter before and after stenting was similar in the two groups (0.99 mm in the sirolimus-stent group and 0.93 mm in the standard-stent group before the procedure and 2.37 and 2.36 mm, respectively, afterward). However, at six months, the minimal luminal diameter was markedly larger in the sirolimus-stent group (2.29 mm, vs. 1.56 mm in the standard-stent group; $P<0.001$); consequently, the late loss was smaller (0.07 mm in the sirolimus-stent group vs. 0.82 mm in the standard-stent group, $P<0.001$) and the restenosis rate was lower (0 percent vs. 41.7 percent, $P=0.002$).

Intravascular Ultrasound Evaluation

At six months, intravascular ultrasound examination showed no significant differences between the two groups with respect to the volume of the stent, the volume of the overall vessel, or the volume of the plaque behind the stent. However, the sirolimus-stent group had significantly less neointimal hyperplasia than did the standard-stent group (2 ± 5 vs. 37 ± 28 mm³) and significantly less volume obstruction, defined as the ratio of the volume of hyperplasia to the volume of the stent, multiplied by 100 (1 ± 3 percent vs. 29 ± 20 percent) ($P<0.001$ for both comparisons). These findings are consistent with the

TABLE 2. RESULTS OF SUBSEGMENTAL QUANTITATIVE ANGIOGRAPHIC ANALYSIS.*

VARIABLE	PROXIMAL EDGE			STENTED SEGMENT			DISTAL EDGE		
	SIROLIMUS STENT	STANDARD STENT	P VALUE	SIROLIMUS STENT	STANDARD STENT	P VALUE	SIROLIMUS STENT	STANDARD STENT	P VALUE
Mean diameter (mm)									
Before procedure	2.66 \pm 0.59	2.62 \pm 0.58		—	—		2.33 \pm 0.55	2.41 \pm 0.58	
After procedure	2.78 \pm 0.55	2.78 \pm 0.53		2.83 \pm 0.41	2.82 \pm 0.40		2.45 \pm 0.47	2.50 \pm 0.52	
At 6 mo	2.73 \pm 0.59	2.55 \pm 0.60	<0.05	2.88 \pm 0.48	2.23 \pm 0.50	<0.001	2.50 \pm 0.53	2.43 \pm 0.52	
Minimal luminal diameter (mm)									
Before procedure	2.27 \pm 0.60	2.23 \pm 0.66		0.94 \pm 0.31	0.95 \pm 0.35		1.97 \pm 0.54	2.07 \pm 0.59	
After procedure	2.47 \pm 0.53	2.46 \pm 0.54		2.43 \pm 0.41	2.41 \pm 0.40		2.13 \pm 0.47	2.21 \pm 0.51	
At 6 mo	2.41 \pm 0.58	2.19 \pm 0.64	0.01	2.42 \pm 0.49	1.64 \pm 0.59	<0.001	2.20 \pm 0.51	2.12 \pm 0.51	
Stenosis (% of luminal diameter)									
Before procedure	15.2 \pm 9.1	16.2 \pm 12.2		63.6 \pm 10.7	64.0 \pm 10.2		15.9 \pm 9.4	14.6 \pm 9.8	
After procedure	11.4 \pm 5.0	12.1 \pm 5.2		11.9 \pm 5.9	14.0 \pm 6.8	<0.05	13.0 \pm 5.2	11.7 \pm 5.1	0.057
At 6 mo	12.2 \pm 4.7	15.4 \pm 8.4	<0.001	14.7 \pm 7.0	36.7 \pm 18.1	<0.01	12.2 \pm 4.9	13.2 \pm 6.9	
Late loss (mm)†	0.05 \pm 0.39	0.29 \pm 0.48	<0.001	-0.01 \pm 0.33	0.80 \pm 0.53	<0.001	-0.09 \pm 0.30	0.12 \pm 0.44	<0.001
$\geq 50\%$ restenosis (% of patients)	0	0		0	26.6	<0.001	0	0	

*Plus-minus values are means \pm SD.

†Late loss was defined as the difference between the minimal luminal diameter immediately after placement of the stent and the minimal luminal diameter at six months. The data are for patients for whom both post-procedural and follow-up measurements of the minimal luminal diameter were available.

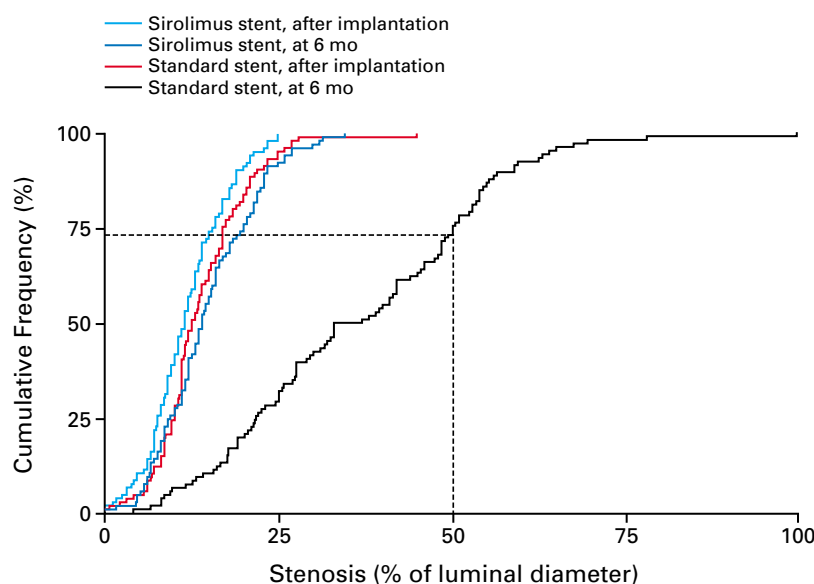


Figure 1. Cumulative Frequency of Stenosis Immediately after Stenting and at Six Months in Patients Who Received Sirolimus-Eluting Stents and in Those Who Received Standard Stents.

The broken lines indicate the percentage of lesions with restenosis (above the line, 22.9 percent) and without restenosis (below the line, 77.1 percent) according to the study definition.

nearly complete suppression of in-stent neointimal hyperplasia by sirolimus. In addition, there was no evidence of an “edge effect,” aneurysm formation, in-stent thrombosis, or persistent dissection.

Adverse Events

Major cardiac events are listed in Table 3. Three patients in each group had a myocardial infarction at the time of stenting. In the sirolimus-stent group, two of the patients with myocardial infarction underwent angiography in the hospital, which showed a patent stent in each. The third patient had a non-Q-wave myocardial infarction, and the angiographic study performed at six months showed a patent stent. One recipient of a standard stent underwent further percutaneous revascularization of the target vessel for the treatment of a lesion other than the index lesion.

During a follow-up period of up to one year, two patients in the standard-stent group (1.7 percent) died: one had a myocardial infarction and died suddenly several weeks later, and the other had a gastric hemorrhage. Two patients in the sirolimus-stent group (1.7 percent) also died: one had a subarachnoid hemorrhage, and the other had gastrointestinal cancer. One patient in each group underwent surgical revascularization of the index target vessel.

Percutaneous revascularization of the target lesion

was performed in 27 recipients of standard stents (22.9 percent) but in none of the recipients of sirolimus-eluting stents ($P=0.001$). Subacute or late thrombotic occlusion of the stent did not occur in either group.

Kaplan-Meier estimates of event-free survival are shown in Figure 2. The overall rate of major cardiac events was 5.8 percent in the sirolimus-stent group and 28.8 percent in the standard-stent group ($P<0.001$). The difference between the two groups was entirely due to the greater need for repeated revascularization of the target vessel in the standard-stent group. No adverse effects were attributable to the sirolimus coating of stents.

DISCUSSION

We found that use of a sirolimus-eluting stent resulted in the virtual elimination of in-stent neointimal hyperplasia; thus, there was no angiographic evidence of restenosis and no need for repeated interventions. Since the introduction of angioplasty, restenosis has been a major factor limiting the long-term success of percutaneous coronary revascularization.¹⁵ The refinement of stenting techniques in the past decade has substantially improved the overall results of the procedure.^{3,4,16,17} Despite considerable efforts to prevent the development of restenosis, however, including systemic or local delivery of biochemical substanc-

TABLE 3. CARDIAC EVENTS IN THE HOSPITAL AND DURING ONE YEAR OF FOLLOW-UP.

EVENT	SIROLIMUS STENT (N=120)	STANDARD STENT (N=118)
Before discharge		
Death — no.	0	0
Myocardial infarction — no.	3	3
Q-wave	2	1
Non-Q-wave	1	2
Coronary-artery bypass grafting — no.	0	0
After discharge		
Death — no.	2	2*
Myocardial infarction — no.	1	2
Q-wave	0	0
Non-Q-wave	1	2
Coronary-artery bypass grafting	1†	1
Percutaneous revascularization of target lesion — no.	0	27
Total — no. (%)	7 (5.8)	34 (28.8)‡
Cumulative event-free survival — %	94.1	70.9§

*Both patients had had previous myocardial infarctions.

†Coronary-artery bypass grafting was performed to treat progressive disease of the left main coronary artery and the ostium of the anterior descending coronary artery, not the target lesion.

‡ $P < 0.001$ for the comparison between the two groups with the use of Fisher's exact test.

§ $P < 0.001$ for the comparison between the two groups with the use of the log-rank test.

es and drugs⁹ and the use of various devices,¹⁸⁻²² additional target-vessel revascularization is required in more than 15 percent of patients.^{8,23} Although catheter-based brachytherapy is effective in the treatment of in-stent restenosis,²⁴ its value in the treatment of primary lesions is less clear. Furthermore, the use of brachytherapy is limited by its high cost and burdensome instrumentation and by the risks inherent in the use of radioisotopes.

In this context, the benefit of the sirolimus-eluting stent in our study was particularly striking. This new device appears to have virtually eliminated the development of neointimal proliferation. Yet its use did not require special implantation techniques or instrumentation and was innocuous within the time frame of the study.

In the group of patients with sirolimus-eluting stents, the percentage of stenosis at six months was essentially the same as that immediately after the procedure and was in all cases less than 35 percent. The virtual absence of late loss in the luminal diameter in this group is consistent with the arrest of in-stent neointimal proliferation by sirolimus. Also noteworthy was the absence of restenosis and major cardiac events in the patients with diabetes who received sirolimus-eluting stents. Whether these effects can be sustained for several years remains to be determined. The results thus far suggest that the use of an appropriate therapeutic agent when growth-factor-induced cell proliferation is at its peak can have substantial effects on the process of in-stent restenosis.

Sirolimus, a macrolide antifungal agent with a

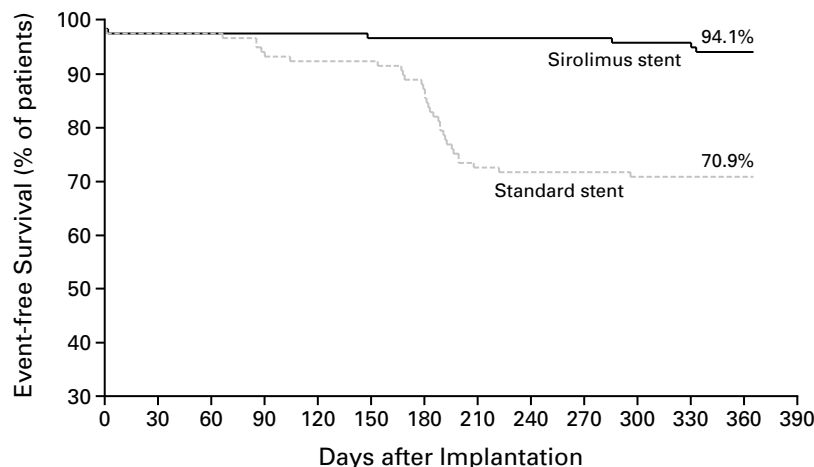


Figure 2. Kaplan-Meier Estimates of Survival Free of Myocardial Infarction and Repeated Revascularization among Patients Who Received Sirolimus-Eluting Stents and Those Who Received Standard Stents.

The rate of event-free survival was significantly higher in the sirolimus-stent group than in the standard-stent group ($P < 0.001$ by the Wilcoxon and log-rank tests).

unique antiproliferative mode of action and powerful immunosuppressant properties, inhibits several regulators of cell-cycle progression and the migration of vascular smooth-muscle cells.²⁵ Yet studies in animals have shown that reendothelialization may occur even while sirolimus is being eluted.²⁶ Moreover, recent experiments in animals have shown that sirolimus blocks inflammation.²⁶ These antiproliferative, antimigratory, and antiinflammatory properties are responsible for the efficacy of sirolimus therapy in preventing acute rejection of renal allografts and arteriopathy of cardiac allografts, as well as in-stent restenosis. The wide safety margin of sirolimus²⁷ and the minuscule amounts of drug released into the blood explain the absence of detectable adverse effects in our trial and in a previous clinical study.¹²

The restenosis rate of 27 percent in the standard-stent group may seem high. However, on the basis of a linear regression model derived from the Stent Restenosis Study and the Benestent I and II studies (unpublished data), the predicted rate of restenosis for our patient cohort was approximately 28 percent. Of the 27 patients in the standard-stent group who underwent revascularization of the target vessel (22.9 percent), 16 did so because of angina or abnormal stress tests and 11 because of angiographic evidence of restenosis.

Despite the absence of late luminal loss in the sirolimus-stent group, reendothelialization presumably occurred, since none of the patients in the group had acute, subacute, or late thrombosis, even though they received combined antiplatelet therapy for only two months. These findings are similar to reported observations in animals.²⁶

We enrolled patients with single lesions that were up to 18 mm long. Whether the positive results in these patients can be expected in patients with more complex or more extensive disease remains to be determined. However, a subgroup analysis showed that the results in patients with diabetes were similar to those in patients without diabetes.

In this trial, 2.5-mm stents were used in 18 percent of the patients randomly assigned to the sirolimus-stent group. Furthermore, division of the treatment groups into thirds according to the vessel diameter revealed virtually identical late luminal loss, even in the smallest arteries.

Stents that deliver drugs are complex devices with three components: the stent, the drug, and the coating. The long-term outcome of treatment with these devices will depend on the response to all three components.

In conclusion, patients with angina who received sirolimus-eluting stents for the treatment of single, primary lesions in native coronary arteries had no angiographic evidence of late luminal loss or in-stent

restenosis at six months, no episodes of thrombosis, and a very low rate of cardiac events at one year.

Supported by a grant from Cordis, a Johnson & Johnson company.
Dr. Falotico is an employee of Cordis.

We are indebted to Drs. Rodolphe Ruffy, Brian Firth, and Dennis Donohoe for their assistance in drafting and reviewing the manuscript.

APPENDIX

The following investigators and institutions participated in the RAVEL study: **Steering Committee** — M.C. Morice (chairperson), Massy, France; P.W. Serruys (cochairperson), Rotterdam, the Netherlands; K. Nijssen, Rotterdam, the Netherlands; C. Bode, Freiburg, Germany; P. Barragan, Marseilles, France; and M. Delattre, Waterloo, Belgium; **Sponsor** — Cordis, Johnson & Johnson, Warren, N.J.; E. Wülfert (program coordinator) and C. Demeyere, Waterloo, Belgium; **Data and Safety Monitoring Board** — J.G.P. Tijssen, Amsterdam; G. Steg, Paris; and P. Vranckx, Rotterdam, the Netherlands; **Data Management** — Cardialysis, Rotterdam, the Netherlands; **Clinical Events Committee** — J. Deckers (chairperson), Rotterdam, the Netherlands; J.A.M. te Riele, Breda, the Netherlands; and L.G.P.M. van Zeijl, Rotterdam, the Netherlands; **Core Angiographic Laboratory** — C. Disco, K. Nijssen, and A. Spierings, Cardialysis, Rotterdam, the Netherlands; **Clinical sites** — M.C. Morice, T. Lefèvre, and Y. Louvard, Institut Cardiovasculaire Paris Sud, Massy, France; P.W. Serruys, M. van den Brand, D. Foley, W. van der Giessen, P. de Feyter, P. Smits, and J. Vos, Thoraxcentrum, Rotterdam, the Netherlands; C. Bode, M. Rave, and C. Holubarsch, Albert Ludwigs Universitätskliniken, Freiburg, Germany; P. Barragan, J.B. Simeoni, C.O. Roquebert, and P. Commeau, Clinique Beauregard, Marseilles, France; G. Schuler, P. Sick, and M. Woinke, Herzzentrum, Leipzig, Germany; G.J. Laarman and F. Kiemeneij, Onze Lieve Vrouwe Gasthuis, Amsterdam; W. Wijns, B. de Bruyne, J. Bartunek, P. de Bruyne, G.R. Heyndrickx, Onze Lieve Vrouwe Kliniek, Aalst, Belgium; J. Fajadet, J. Marco, B. Farah, P. Sousa, and M. Boccalatte, Clinique Pasteur, Toulouse, France; J.L. Guermontprez, Hôpital Européen Georges Pompidou, Paris; A. Colombo, C. di Mario, R. Albiero, and N. Corvaja, Centro Cuore Columbus, Milan, Italy; A. Bartorelli, S. Galli, F. Fabbiochi, P. Montorsi, D. Trabattoni, and A. Loaldi, Centro Cardiologico Monzino, Milan, Italy; G. Guagliumi, O. Valsecchi, M. Tespili, A. Vassileva, and A. Saimo, Ospedali Riuniti di Bergamo, Bergamo, Italy; F. Molnár, R.G. Kiss, L. Major, and G. Bokori, Semmelweis Egyetem Egészségtudományi Kar, Budapest, Hungary; E. Ban Hayashi, I. Sanchez, J. Gaspar, R. Villavicencio, and M.A. Pena Duque, Instituto Nacional de Cardiologia, Mexico City, Mexico; J.E. Sousa, E. Sousa, A.S. Abizaid, A. Abizaid, A. Sousa, F. Feres, L.A. Mattos, M. Costa, and R. Staico, Instituto Dante Pazzanese de Cardiologia, São Paulo, Brazil; M. Perin, E. Ribeiro, E. Martinez, P. Soares, and E. Demartino, University Hospital of São Paulo, São Paulo, Brazil; D. Blanchard and O. Bar, Clinique Saint-Gatien, Tours, France; A. Cribier, H. Eltchaninoff, Centre Hospitalier Universitaire de Rouen, Rouen, France.

REFERENCES

1. Sigwart U, Puel J, Mirkovitch V, Joffe F, Kappenberg L. Intravascular stents to prevent occlusion and restenosis after transluminal angioplasty. *N Engl J Med* 1987;316:701-6.
2. Roubin GS, Cannon AD, Agrawal SK, et al. Intracoronary stenting for acute and threatened closure complicating percutaneous transluminal coronary angioplasty. *Circulation* 1992;85:916-27.
3. Serruys PW, de Jaegere P, Kiemeneij F, et al. A comparison of balloon-expandable-stent implantation with balloon angioplasty in patients with coronary artery disease. *N Engl J Med* 1994;331:489-95.
4. Fischman DL, Leon MB, Baim D, et al. A randomized comparison of coronary-stent placement and balloon angioplasty in the treatment of coronary artery disease. *N Engl J Med* 1994;331:496-501.
5. Serruys PW, de Bruyne B, Carlier S, et al. Randomized comparison of primary stenting and provisional balloon angioplasty guided by flow velocity measurement. *Circulation* 2000;102:2930-7.
6. Dussaillant GR, Mintz GS, Pichard AD, et al. Small stent size and intimal hyperplasia contribute to restenosis: a volumetric intravascular ultrasound analysis. *J Am Coll Cardiol* 1995;26:720-4.
7. Hoffmann R, Mintz GS, Dussaillant GR, et al. Patterns and mechanisms of in-stent restenosis: a serial intravascular ultrasound study. *Circulation* 1996;94:1247-54.
8. Serruys PW, Unger F, Sousa E, et al. Comparison of coronary-artery

bypass surgery and stenting for the treatment of multivessel disease. *N Engl J Med* 2001;344:1117-24.

9. de Feyter PJ, Vos J, Rensing BJ. Anti-restenosis trials. *Curr Interv Cardiol Rep* 2000;2:326-31.

10. Burke SE, Lubbers NL, Chen Y-W, et al. Neointimal formation after balloon-induced vascular injury in Yucatan minipigs is reduced by oral rapamycin. *J Cardiovasc Pharmacol* 1999;33:829-35.

11. Gallo R, Padurean A, Jayaraman T, et al. Inhibition of intimal thickening after balloon angioplasty in porcine coronary arteries by targeting regulators of the cell cycle. *Circulation* 1999;99:2164-70.

12. Sousa JE, Costa MA, Abizaid A, et al. Lack of neointimal proliferation after implantation of sirolimus-coated stents in human coronary arteries: a quantitative coronary angiography and three-dimensional intravascular ultrasound study. *Circulation* 2001;103:192-5.

13. Campeau L. Grading for angina pectoris. *Circulation* 1976;54:522-3.

14. Braunwald E. Unstable angina: a classification. *Circulation* 1989;80:410-4.

15. Holmes DR Jr, Vlietstra RE, Smith HC, et al. Restenosis after percutaneous transluminal coronary angioplasty (PTCA): a report from the PTCA Registry of the National Heart, Lung, and Blood Institute. *Am J Cardiol* 1984;53:Suppl:77C-81C.

16. Serruys PW, van Hout B, Bonnier H, et al. Randomised comparison of implantation of heparin-coated stents with balloon angioplasty in selected patients with coronary artery disease (Benestent II). *Lancet* 1998;352:673-81. [Erratum, *Lancet* 1998;352:1478.]

17. Versaci F, Gasparone A, Tomai F, Crea F, Chiariello L, Gioffrè PA. A comparison of coronary-artery stenting with angioplasty for isolated stenosis of the proximal left anterior descending coronary artery. *N Engl J Med* 1997;336:817-22.

18. Kastrati A, Schomig A, Dirschinger J, et al. Increased risk of restenosis

after placement of gold-coated stents: results of a randomized trial comparing gold-coated with uncoated steel stents in patients with coronary artery disease. *Circulation* 2000;101:2478-83.

19. Kuntz RE, Safian RD, Levin MJ, Reis GJ, Diver DJ, Baim DS. Novel approach to the analysis of restenosis after the use of three new coronary devices. *J Am Coll Cardiol* 1992;19:1493-9.

20. Mehran R, Dangas G, Mintz GS, et al. Treatment of in-stent restenosis with excimer laser coronary angioplasty versus rotational atherectomy: comparative mechanisms and results. *Circulation* 2000;101:2484-9.

21. Topol EJ, Leya F, Pinkerton CA, et al. A comparison of directional atherectomy with coronary angioplasty in patients with coronary artery disease. *N Engl J Med* 1993;329:221-7.

22. Baim DS, Cutlip DE, Sharma SK, et al. Final results of the Balloon vs Optimal Atherectomy Trial (BOAT). *Circulation* 1998;97:322-31.

23. Mudra H, di Mario C, de Jaegere P, et al. Randomized comparison of coronary stent implantation under ultrasound or angiographic guidance to reduce stent restenosis (OPTICUS Study). *Circulation* 2001;104:1343-9.

24. Teirstein PS, Massullo V, Jani S, et al. Catheter-based radiotherapy to inhibit restenosis after coronary stenting. *N Engl J Med* 1997;336:1697-703.

25. Marx SO, Marks AR. The development of rapamycin and its application to stent restenosis. *Circulation* 2001;104:852-5.

26. Suzuki T, Kopia G, Hayashi S, et al. Stent-based delivery of sirolimus reduces neointimal formation in a porcine coronary model. *Circulation* 2001;104:1188-93.

27. Saunders RN, Metcalfe MS, Nicholson ML. Rapamycin in transplantation: a review of the evidence. *Kidney Int* 2001;59:3-16.

Copyright © 2002 Massachusetts Medical Society.

ELECTRONIC ACCESS TO THE JOURNAL'S CUMULATIVE INDEX

At the *Journal's* site on the World Wide Web (<http://www.nejm.org>) you can search an index of all articles published since January 1975 (abstracts 1975-1992, full-text 1993-present). You can search by author, key word, title, type of article, and date. The results will include the citations for the articles plus links to the abstracts of articles published since 1993. For nonsubscribers, time-limited access to single articles and 24-hour site access can also be ordered for a fee through the Internet (<http://www.nejm.org>).